



Case report

Orthognathic correction and corticobasal implant-supported prostheses as a treatment modality for partial edentulism with mandibular prognathism: A case report and review of literature

Abdelnasir G. Ahmad^a, Motaz Osman^b, Fadia Awadalkreem^{c,*}

^a International University of Africa, Oral and Maxillofacial Surgery Department, Khartoum, Sudan

^b Implant Department, Khartoum Teaching Dental Hospital, Federal Ministry of Health, Khartoum, Sudan

^c Department of Prosthodontics, RAK College of Dental Sciences, Ras Al-Khaimah, United Arab Emirates

ARTICLE INFO

Keywords:

Corticobasal implants
Implant-supported prostheses
Mandibular prognathism
Orthognathic surgery
Case report

ABSTRACT

Introduction: Mandibular prognathism manifests as elongation of the mandible in the anteroposterior direction, resulting in a sunken appearance of the middle third of the face and sad look of the eyes. It adversely affects esthetics, function, and oral health, reducing the patients' self-esteem. It therefore presents a significant challenge.

Presentation of case: A 23-year-old woman presented with prognathic features characterized by mandibular protrusion, maxillary retrusion, a prominent chin, and reduce self-esteem. Intraoral examination revealed multiple extracted teeth, severe fracture of the crown at 23, mobility of the fixed prosthesis on 13, 14, 15, and 16, a root stump of 18, and periodontally compromised teeth (31, 32, 33, 41, and 42).

A multidisciplinary team formulated the following treatment plan: stage I, orthognathic osteotomy to retrude the mandible at 34 and 44; stage II, fabrication of transitional acrylic partial dentures; and stage III: fabrication of definitive corticobasal implant-supported prostheses. The patient was delighted with the treatment and complied with the oral hygiene instructions and follow-up program. After 7 years of function, the patient presented without complaints and exhibited significant improvement in oral health, self-esteem, and quality of life.

Discussion: The management of mandibular prognathism requires a multidisciplinary approach. The treatment implemented was considered the optimal option that aligned with the recommendations of several researchers to reduce facial disfigurement and rehabilitate the edentulous state.

Conclusion: The use of corticobasal implant-supported prostheses for the rehabilitation of patients with partial edentulism can significantly improve the treatment outcome following orthognathic surgery in cases with mandibular prognathism.

1. Introduction

Dentofacial deformities (DFDs) denote a significant deviation from the average proportions of the maxillo-mandibular apparatus [1]. The World Health Organization considers it one of the most critical oral health problems after caries and periodontal disease [2]. It adversely affects the patient's esthetics, function, and oral health [2,3], self-esteem, and quality of life [1–3].

The exact prevalence of DFDs has not been established [4,5]; it ranges from 39 to 93% in children and adolescents [2,6]. Approximately 5% of the population of the UK and USA exhibits features of DFDs that require orthognathic surgery as a part of dental treatment [4].

Class III malocclusion (mandibular prognathism) is reportedly the most prevalent of all DFDs [4]. Several studies conducted in Hong Kong [4,7], Brazil [8], the UK [9], Norway, and the USA have supported this observation [4,10].

Mandibular prognathism manifests as elongation of the mandible in the anteroposterior direction, resulting in a sunken and faded appearance in the middle third of the face and sad looks in the eyes [11], reducing the patient's confidence and self-esteem. Therefore, it presents a significant challenge [1–3,11].

The importance of orthognathic surgery is undeniable, especially with the advancement of dental treatment and increased demands for highly esthetic outcomes. Orthognathic surgery includes several

* Corresponding author.

E-mail addresses: fadiadent@hotmail.com, fadia.alfateh@rakmhsu.ac.ae (F. Awadalkreem).

<https://doi.org/10.1016/j.ijscr.2022.107219>

Received 6 April 2022; Received in revised form 15 May 2022; Accepted 15 May 2022

Available online 18 May 2022

2210-2612/© 2022 The Authors. Published by Elsevier Ltd on behalf of IJS Publishing Group Ltd. This is an open access article under the CC BY-NC-ND license (<http://creativecommons.org/licenses/by-nc-nd/4.0/>).

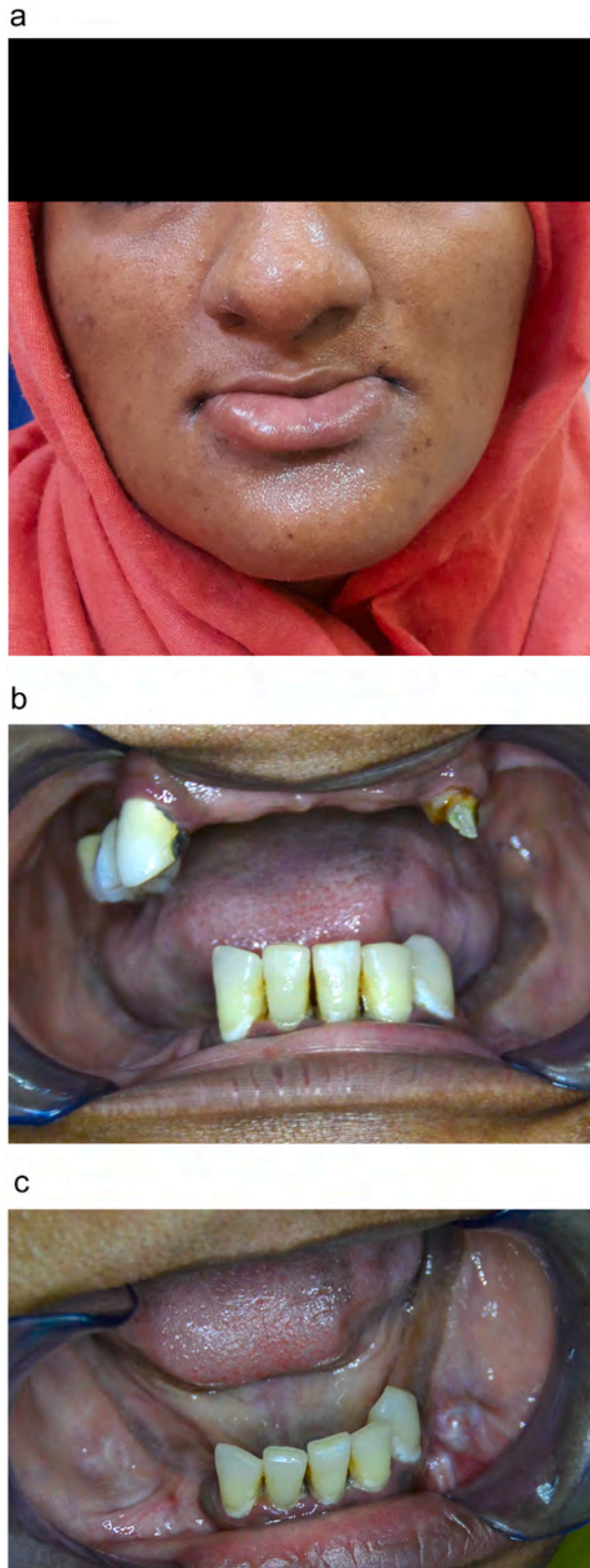


Fig. 1. Patient's clinical presentation.

- a) Extra-oral photograph of the patient (frontal view) showing a prognathic facial form with a prominent chin, protruded mandible, and retruded maxilla;
- b) Intraoral clinical photograph of the patient showing the maxillary jaw with a severely destructed crown with 23 and a badly constructed fixed prosthesis with 13, 14, and 15;
- c) Intraoral clinical photograph of the patient showing a Kennedy class I mandibular arch with a periodontally compromised status in 31, 32, 33, 41, and 42; and
- d) Preoperative computed tomography scan of the patient.

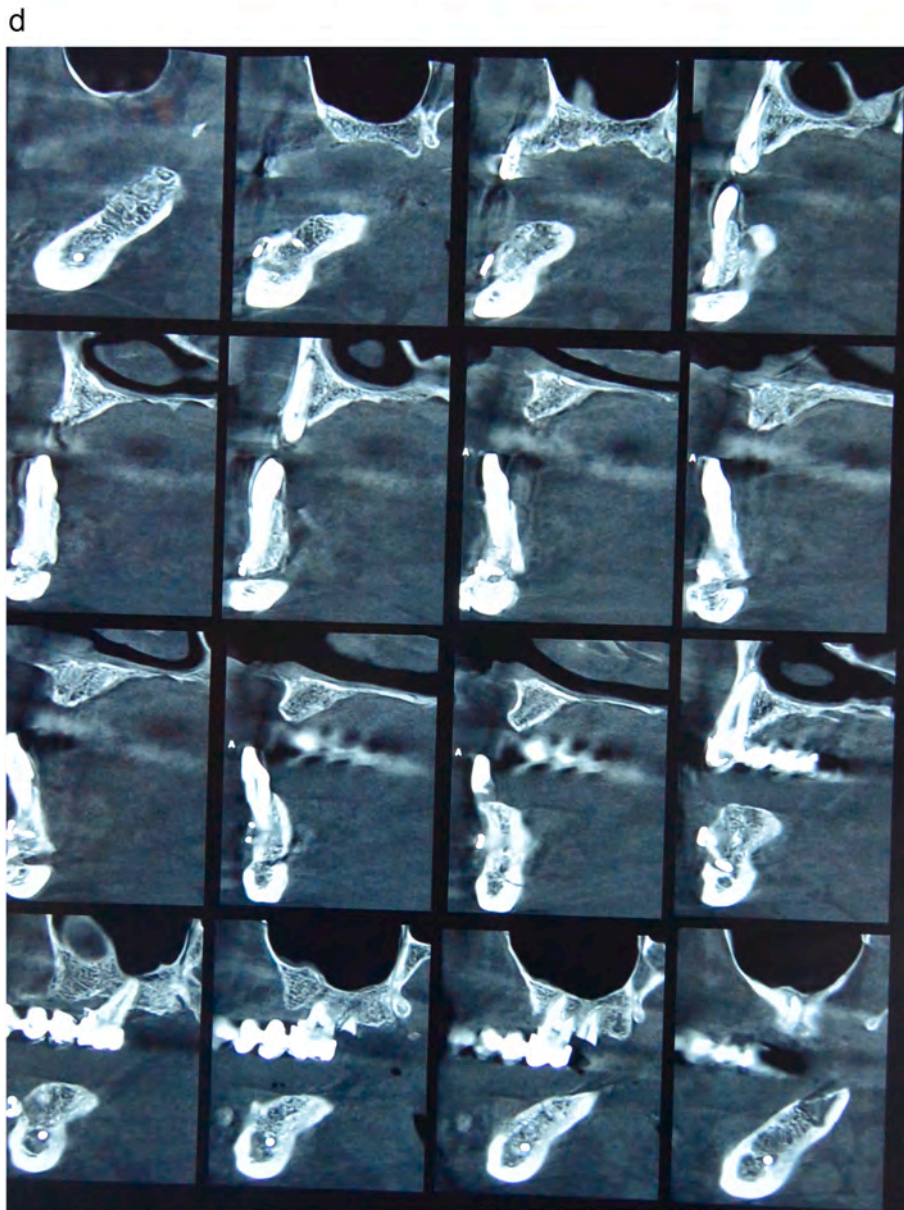


Fig. 1. (continued).

procedures in maxillofacial surgery, which are designed to correct deformities in the structure of the facial skeleton [12]. The word “orthognathic” originates from a Greek word meaning “straight bones” [12]. The desired outcome can be achieved through repositioning of the craniofacial region, which entails correction with osteotomy followed by stabilization and fixation in a new position [13].

Orthognathic surgery plays a significant role in the management of severe malocclusion, facial profile discrepancies, including mandibular prognathism, and obstructive sleep apnea [14–16]. Several orthognathic surgical approaches have been proposed, such as maxillary protrusion (LeFort I osteotomy), mandibular retrusion through mandibular osteotomy, bilateral sagittal split osteotomy, or both, with or without osseous genioplasty [14,16].

The first mandibular osteotomy was performed in 1849 by the American surgeon Simon P. Hullien for the management of mandibular prognathism with a resultant edge-to-edge occlusion [16].

The development of a treatment protocol involving orthognathic surgery with pre-and post-surgical orthodontic treatment for the treatment of patients with skeletal profile and malocclusion discrepancies

signaled a paradigm shift in the 1970s [16]. The chief disadvantages of this approach are the prolonged treatment time and transitional esthetic limitations [16].

In 1988, Behrman and Behrman introduced the surgery-first approach to overcome the prolonged time needed for treatment; however, some unpredictable outcomes were noted [17]. Therefore, a modified approach has been proposed, which includes preoperative orthodontic treatment of less than 6 months [18].

A new protocol has been adopted for patients with partial and complete edentulism, including orthognathic surgery and implant insertion with or without bone grafting, as the lack of supporting teeth may prohibit or even eliminate the need for orthodontic treatment [19–21]. Moreover, the demand for replacing lost teeth to improve the final esthetic outcomes is high. The number and sequences of the treatment protocol vary according to the patient's condition and experience of the multidisciplinary team [19–21].

Currently, corticobasal implants have been used for the rehabilitation of patients with compromised ridge support as an alternative to bone grafting, yielding a high success rate [22,23].

However, there is a lack of knowledge regarding the use of corticobasal implants in connection with orthognathic surgery. To our knowledge, this is the first case report describing the rehabilitation of a partially edentulous patient using orthodontic surgery and corticobasal fixed implant-supported prostheses. This work has been reported according to the SCARE criteria [24].

2. Presentation of the case

A 23-year-old woman with a complaint of poor esthetics, which considerably affected her social interactions, was referred to the second author's academic institution. The patient was severely depressed and displayed significant ignorance regarding her oral health status. The patient reported no relevant medical, family, or drug history. Extraoral examination revealed a prognathic face with a protruded mandible, retruded maxilla, and prominent chin (Fig. 1a). Intraoral examination revealed multiple missing teeth, severe destruction of the clinical crown at 23, mobility of the fixed prosthesis at 13, 14, 15, and 16, a root stump with 18, and several periodontally compromised teeth (31, 32, 33, 41, and 42) (Fig. 1b, c).

2.1. Treatment

A multidisciplinary team was formed, including an expert oral maxillofacial surgeon, orthodontist, and prosthodontists specializing in removable and fixed prostheses. Radiographic evaluation was performed using digital panoramic radiography (Planmeca Pro max, Finland) and computed tomography, in addition to cephalometric analyses, to evaluate all possible treatment options (Fig. 1d). The different treatment options were discussed with the patient in detail. The patient refused the bi-maxillary and mandibular osteotomy approach as her main concern was only the mandibular protrusion.

Thus, a treatment plan was formulated involving bilateral mandibular osteotomy with step back in the region of the mandibular first premolars, extraction of the hopeless maxillary teeth, and prosthetic rehabilitation using fixed corticobasal implant-supported prostheses. Informed consent was obtained from the patient for both treatment and publication of this report.

2.2. Orthognathic surgery

Primary impressions were made using irreversible hydrocolloid impression material, i.e., alginate (Hydrogum, Zhermack) to fabricate

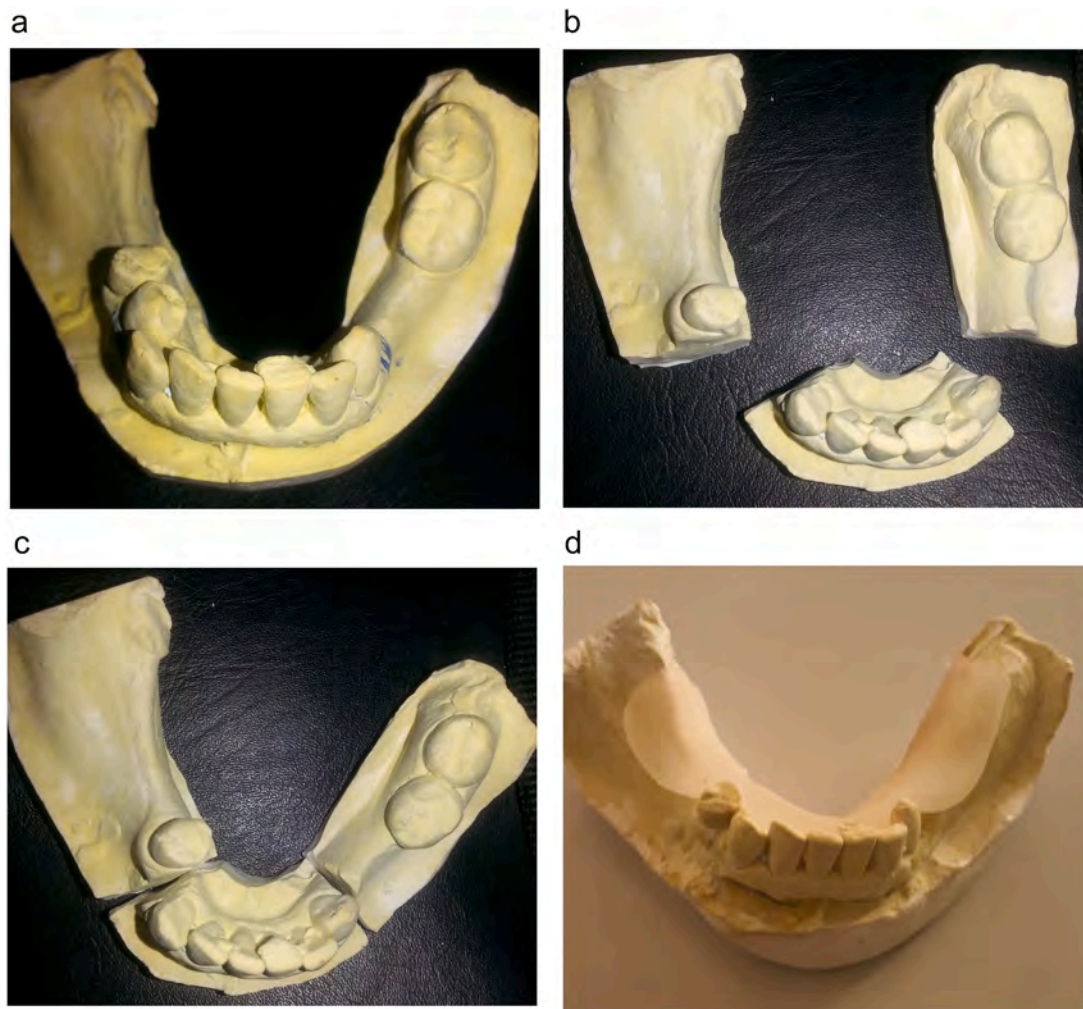


Fig. 2. Photograph showing preoperative preparation for orthognathic surgery on the mandibular dental stone model of the patient.

a) The mandibular cast was demarcated for the surgery in the of the 34 and 44 regions;

b) The model was sectioned in the region of 34 and 44;

c) The model was reassembled after the extraction of 34 and 44;

d) A heat-cured stabilizing splint was constructed over the assembled model to use for fixation and immobilization of the mandibular bone during the post-operative period.

preoperative casts on which the planned surgical procedure was performed. Wafer and stabilizing splints were constructed using clear auto-polymerizing acrylic resin [24,25] (Fig. 2a, b, c, d).

Surgical osteotomy was performed under general anesthesia by a specialized maxillofacial surgeon with more than 10 years of experience, and screws and plates were used to stabilize the mandibular bone with the aid of acrylic splints (Fig. 3a). The patient was scheduled for a follow-up appointment after 2 weeks; her skeletal profile appeared excellent, with a positive impact on her self-esteem (Fig. 3b, c). Transitional maxillary and mandibular acrylic prostheses were fabricated.

2.3. Definitive prostheses: fixed implant-supported prostheses

Six months later, the patient was scheduled for the final phase of treatment. First, she was asked to rinse her mouth with 10% betadine for 1 min. Local anesthesia was induced with 2% lidocaine with epinephrine 1:100000. Thereafter, implant osteotomy was performed: nine BSC® implants of the appropriate lengths and diameters were inserted into the maxilla, and six implants were inserted into the mandible (Fig. 4a). Amoxicillin 1 g and metronidazole 500 mg were administered for antibiotic coverage, and analgesia was achieved with diclofenac potassium 50 mg (Rapidus). Digital panoramic radiography and cone-beam computed tomography were performed postoperatively (Fig. 4b, c, d, e).

Impression copings were secured, and the final impression was acquired using vinyl polysiloxane (Monophase; Ivoclar Vivadent AG). The next day, a metal framework was constructed to splint the implants together and a trial was performed. On the third day, the final prosthesis was inserted and cemented with luting cement (Fuji cement, GC Corporation, Tokyo, Japan) and adjusted for optimal occlusion (Fig. 5a, b, c). The patient was provided with oral hygiene instructions and scheduled for follow-up after one week.

The patient reported no complaints on the follow-up visit and was highly satisfied with the treatment outcomes. A periodic follow-up program was formulated, including a dental visit every 6 months for clinical and radiographic assessments. After 7 years of follow-up, the patient was delighted and exhibited optimal peri-implant health without implant- or prostheses-related complications (Fig. 5d).

3. Discussion

The management of mandibular prognathism presents a clinical challenge [1]. Treatment should aim to sustain the patient's oral health and improve his/her esthetic appearance, function, and quality of life [1,3].

The successful management of any dentofacial abnormalities requires a multidisciplinary team approach, which was implemented in the present case [25,26]. The excellent communication and close working relationship between the team members directly influence the treatment success [25,26].

Several treatment options have been considered for the management of mandibular prognathism, including orthognathic surgery [12–16,19–22]. The present patient was a 23-year-old woman whose primary concern was her esthetic appearance, causing severe depression that adversely affected oral health, resulting in several missing teeth and severe periodontal breakdown. Thus, the selected treatment was considered as the optimal option that met the recommendations of several studies to reduce facial disfigurement and rehabilitate the edentulous status. Khojasteh et al. [19] and Grecchi et al. [20] described the successful use of implant assisted prostheses in patients with mandibular prognathism.

The use of wafer and stabilizing splints played a substantial role in the successful outcomes in this case as these devices eliminate the risk of intra-operative occlusal discrepancies and the post-operative healing period [25,26].

Moreover, fixed corticobasal implant-supported prostheses provided the patient with an immediate functional fixed prosthesis with a high

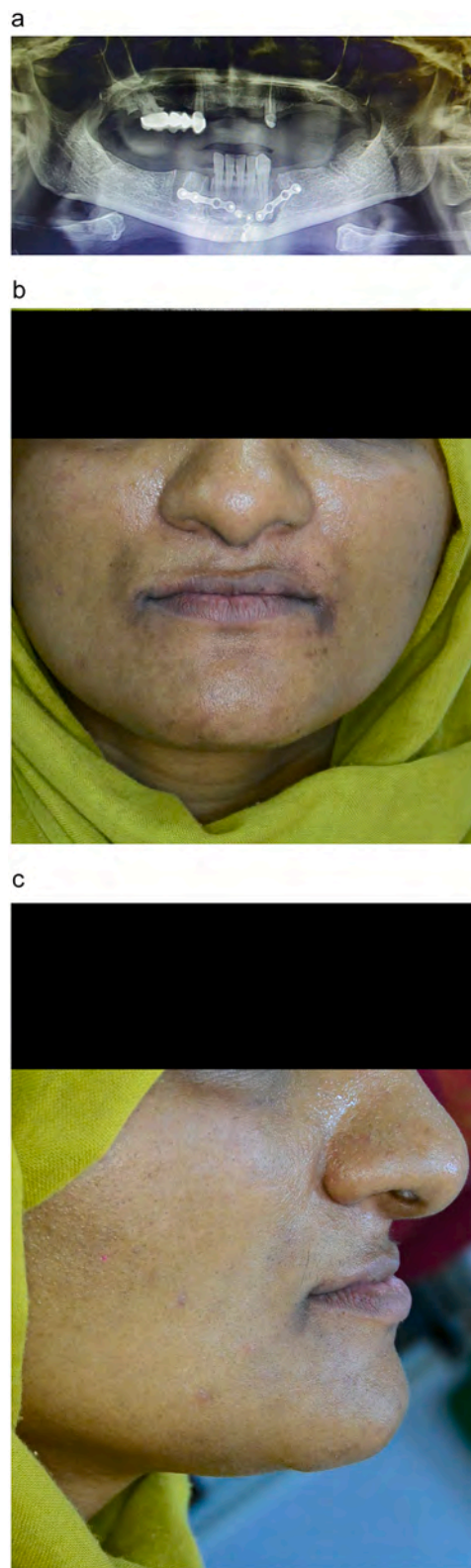


Fig. 3. Patient's clinical presentation 2 weeks after orthognathic surgery. a) Extra-oral frontal view of the patient showing an improvement in the patient's facial; b) Extra-oral lateral view of the patient; c) Panoramic radiograph showing fracture in the clinical crown of 23, fixed prosthesis with 13, 14, and 15, root stump with 18, and periodontal compromise with 33, 32, 31, 41, and 42. Screw and plates were used to stabilize the surgical area.

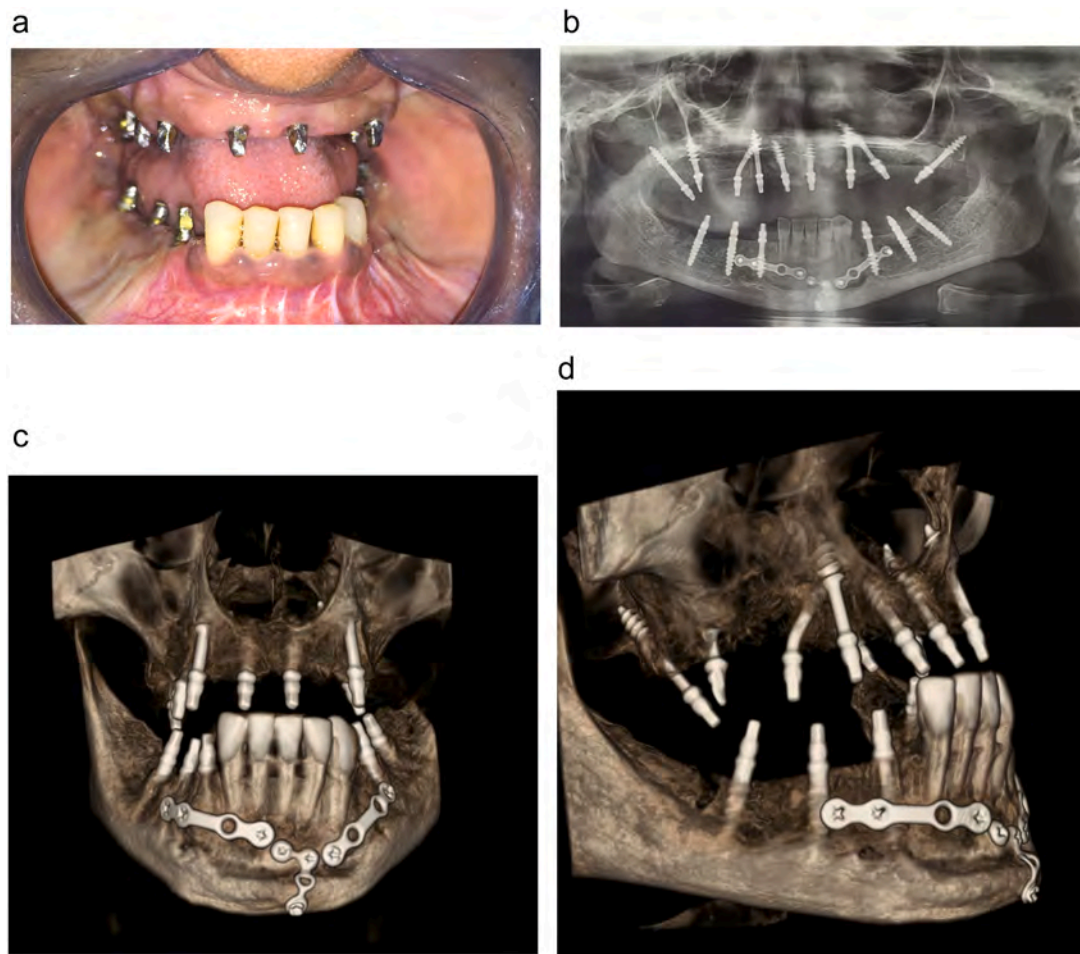


Fig. 4. Radiographic images of the patient after implant insertion

- a) Intraoral clinical photograph of the patient showing the implant distribution.
 b) Panoramic radiograph showing the placement of the maxillary and mandibular implants;
 c) Three-dimensional (3D) view of the maxilla and mandible using cone-beam computed tomography showing the distribution of the maxillary and mandibular implants, screws, and plates (Frontal view);
 d) 3D view of the right side of the maxilla and mandible using cone-beam computed tomography showing the placement of the maxillary and mandibular implants, screws and plates;
 e) 3D view of the left side of the maxilla and mandible with cone-beam computed tomography showing the distribution of the maxillary and mandibular implants and screws and plates used for fixation after orthognathic surgery.

success rate, as reported by previous studies [22,23]. Furthermore, they eliminate the need for bone grafting and its associated risk factors [22,23].

The high satisfaction level reported by the patient was in line with that reported for orthognathic surgery (90–100%) [1,27] and cortico-basal implants [22,23].

4. Conclusion

The treatment of patients with mandibular prognathism necessitates a high degree of planning and a multidisciplinary approach. Good communication between team members and vast experience are key to successful treatment.

The use of corticobasal implant-supported prostheses for the rehabilitation of partially edentulous patients can significantly improve the treatment outcome following orthognathic surgery in those with mandibular prognathism. It can successfully restore patients' esthetics, masticatory ability, and phonetics and improve their self-esteem and quality of life.

Provenance and peer review

Not commissioned, externally peer-reviewed.

Sources of funding

This research did not receive any specific grant from funding agencies in the public, commercial, or not-for-profit sectors.

Ethical approval

The ethical approval was obtained from the ethical committee of the Khartoum Dental Teaching Hospital, Federal Ministry of Health, Khartoum, Sudan. The research was registered at the Research Registry with the unique identifying number: researchregistry 7913.

Consent

Written informed consent was obtained from the patient for publication of this case report and accompanying images.

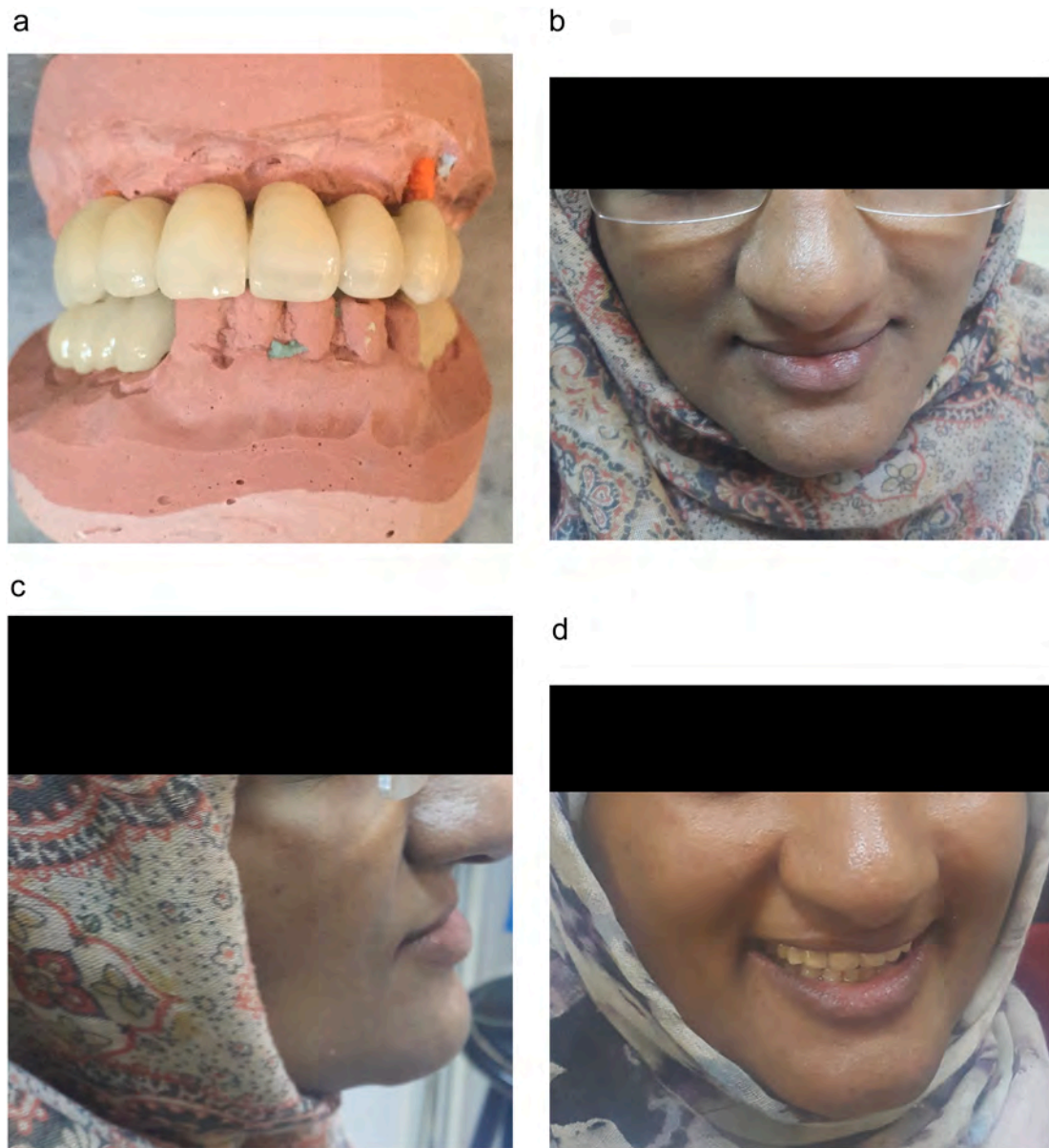

Fig. 5. Final maxillary and mandibular corticobasal implant-supported prostheses.

- a) Final prostheses before being insertion into the patient's mouth;
 b) Frontal view of the patient after the final maxillary and mandibular basal-implant supported prostheses;
 c) Lateral view of the patient after the final maxillary and mandibular basal-implant supported prostheses;
 d) Frontal view of the patient showing the patient's face at the follow-up visit.

Research registration

The research approved by the research ethical committee of Khartoum Dental Teaching Hospital, Federal Ministry of Health, Khartoum, Sudan.

The research was registered at the Research Registry with the unique identifying number: researchregistry 7913.

Guarantor

Abdelnasir G. Ahmad.
 Motaz Osman.
 Fadia Awadalkreem.

CRediT authorship contribution statement

Ahmad A contributed to the conceptualization, treating the patient, supervision of the case, and writing the manuscript.

Osman M contributed to the conceptualization, validation, treating the patient, and supervision of the case.

Awadalkreem F contributed to the conceptualization, treating the patient, editing, supervision of the case, and finalization of the manuscript.

Declaration of competing interest

The authors declare no conflicts of interest in connection with this research and manuscript.

References

- [1] V. Duarte, C. Zoror, J. Villanueva, M. Andreo, M. Dallaseria, J. Salazar, et al., Oral health-related quality of life changes in patients with dentofacial deformities Class II and III after orthognathic surgery: a systematic review and meta-analysis, *Int. J. Environ. Res. Public Health* 19 (2022) 1940.
- [2] N. Cenzato, A. Nobili, C. Maspero, Prevalence of dental malocclusions in different geographical areas: scoping review, *Dent. J. (Basel)* 9 (2021) 117.
- [3] F.S. Ryan, M. Barnard, S.J. Cunningham, Impact of dentofacial deformity and motivation for treatment: a qualitative study, *Am. J. Orthod. Dentofac. Orthop.* 141 (2012) 734–742.
- [4] D.A.A. Marlière, T.E. Costa, S.M. Barbosa, R.A. Pereira, H.D.M. Chaves Netto, Alteration of occlusal plane in orthognathic surgery: clinical features to help treatment planning on Class III patients, *Case Rep. Dent.* 2018 (2018) 2495262.
- [5] F. Eslamipour, A. Borzabadi-Farahani, B.T. Le, M. Shahmoradi, A retrospective analysis of dentofacial deformities and orthognathic surgeries, *Ann. Maxillofac. Surg.* 7 (2017) 73–77.
- [6] M. Mtaya, P. Brudvik, A.N. Astrøm, Prevalence of malocclusion and its relationship with socio-demographic factors, dental caries, and oral hygiene in 12- to 14-year-old Tanzanian schoolchildren, *Eur. J. Orthod.* 31 (2009) 467–476.
- [7] C.T. Lee, L.K. Cheung, B.S. Khambay, A.Y. Ayoub, P. Benington, Dentofacial deformities and orthognathic surgery in Hong Kong and Glasgow, *Ann. R. Australas. Coll. Dent. Surg.* 22 (2014) 113–115.
- [8] E.M. Boeck, N. Lunardi, S. Pinto Ados, K.E. Pizzol, R.J. Boeck Neto, Occurrence of skeletal malocclusions in Brazilian patients with dentofacial deformities, *Braz. Dent. J.* 22 (2011) 340–345.
- [9] C. Harrington, J.R. Gallagher, A. Borzabadi-Farahani, A retrospective analysis of dentofacial deformities and orthognathic surgeries using the index of orthognathic functional treatment need (IOFTN), *Int. J. Pediatr. Otorhinolaryngol.* 79 (2015) 1063–1066.
- [10] W.R. Proffit, T.H. Jackson, T.A. Turvey, Changes in the pattern of patients receiving surgical-orthodontic treatment, *Am. J. Orthod. Dentofac. Orthop.* 143 (2013) 793–798.
- [11] R.G. López, S.C. Paz, S.S. Velázquez, Correcting a class III malocclusion with pre surgical orthodontics and oblique ramus osteotomy. Case report, *Rev. Mex. Ortod.* 2 (2014) 120–127.
- [12] E. Zawiślak, S. Przywitowski, A. Olejnik, H. Gerber, P. Golusiński, R. Nowak, Current trends in orthognathic surgery in Poland—a retrospective analysis of 124 cases, *Appl. Sci.* 11 (2021) 6439.
- [13] H.L. Obwegeser, Orthognathic surgery and a tale of how three procedures came to be: a letter to the next generations of surgeons, *Clin. Plast. Surg.* 34 (2007) 331–355.
- [14] S. Naran, D.M. Steinbacher, J.A. Taylor, Current concepts in orthognathic surgery, *Plast. Reconstr. Surg.* 141 (2018) 925e–936e.
- [15] H.J. Seo, Y.K. Choi, Current trends in orthognathic surgery, *Arch. Craniofac. Surg.* 22 (2021) 287–295.
- [16] R.T. Wu, A.T. Wilson, C.S. Gary, D.M. Steinbacher, Complete reoperation in orthognathic surgery, *Plast. Reconstr. Surg.* 143 (2019) 1053e–1059e.
- [17] S.J. Behrman, D.A. Behrman, Oral surgeons' considerations in surgical orthodontic treatment, *Dent. Clin. N. Am.* 32 (1988) 481–507.
- [18] E.W. Ko, S.S. Hsu, H.Y. Hsieh, Y.C. Wang, C.S. Huang, Y.R. Chen, Comparison of progressive cephalometric changes and postsurgical stability of skeletal Class III correction with and without presurgical orthodontic treatment, *J. Oral Maxillofac. Surg.* 69 (2011) 1469–1477.
- [19] A. Khojasteh, L. Payaminia, M. Alikhasi, Implant assisted ortho-surgery in edentulous jaws: a clinical report, *Clin. Case Rep.* 3 (2015) 920–926.
- [20] F. Grecchi, I. Zollino, A. Parafioriti, G. Mineo, A. Pricolo, F. Carinci, One-step oral rehabilitation by means of implants' insertion, Le Fort I, grafts, and immediate loading, *J. Craniofac. Surg.* 20 (2009) 2205–2210.
- [21] J.I. Cawood, P.J.W. Stoelting, J.J.A. Brouns, Reconstruction of the severely reabsorbed (class VI) maxilla. A two-step procedure, *Int. J. Oral Maxillofac. Surg.* 23 (1994) 219–225.
- [22] F. Awadalkreem, N. Khalifa, A.G. Ahmad, A.M. Suliman, M. Osman, Rehabilitation of an irradiated marginal mandibulectomy patient using immediately loaded basal implant-supported fixed prostheses and hyperbaric oxygen therapy: a 2-year follow-up, *Int. J. Surg. Case Rep.* 71 (2020) 297–302.
- [23] F. Awadalkreem, N. Khalifa, A.G. Ahmad, A.M. Suliman, M. Osman, Prosthetic rehabilitation of maxillary and mandibular gunshot defects with fixed basal implant-supported prostheses: a 5-year follow-up case report, *Int. J. Surg. Case Rep.* 68 (2020) 27–31.
- [24] R.A. Agha, T. Franchi, C. Sohrabi, G. Mathew, A. Kerwan, SCARE Group, The SCARE 2020 guideline: updating consensus Surgical Case Report (SCARE) guidelines, *Int. J. Surg.* 84 (2020) 226–230.
- [25] G.A. Ghaly, P.A. Bowman, G.T. McIntyre, Modified wafer for orthognathic surgery in partially edentulous patients, *Br. J. Oral Maxillofac. Surg.* 58 (2020) 486–487.
- [26] S.J. Cunningham, A. Johal, Orthognathic correction of dento-facial discrepancies, *Br. Dent. J.* 218 (2015) 167–175.
- [27] J.R. Sandy, G.H. Irvine, A. Leach, Update on orthognathic surgery, *Dent. Update* 28 (337–42) (2001) 344–345.