Cranio-maxillofacial

Implant Directions®

Vol. 14 N° 1 January 2020 English Edition

Case Report:

Multi-unit connection for the Strategic Implant®: an innovative way for achieving retrievability of prosthetics on fully polished single piece implants used in an immediate loading protocol

Case Report:

Full maxilla and partial mandible reconstruction-case report and considerations regarding necessary number of implants and the necessity for the incorporation of a rigidly cemented metal-enforced first bridge for immediate loading treatment protocols

ISSN 1864-1199 / e-ISSN 1864-1237

Published by IF Publishing, Germany

The Foundation of Knowledge

Editorial board

Annual Subscription
Euro 2.800

Contact
publishing@implantfoundation.org

CMF.Impl.dir.
ISSN 1864-1199
e-ISSN 1864-1237

Disclaimer

Hazards
Great care has been taken to maintain the accuracy of the information contained in this publication. However, the publisher and/or the distributer and/or the editors and/or the authors cannot be held responsible for errors or any consequences arising from the use of the information contained in this publication. The statements or opinions contained in editorials and articles in this publication are solely those of the authors thereof and not of the publisher, and/or the distributer, and/or the IIF.
The products, procedures and therapies described in this work are hazardous and are therefore only to be applied by certified and trained medical professionals in environment specially designed for such procedures. No suggested test or procedure should be carried out unless, in the user's professional judgment, its risk is justified. Whoever applies products, procedures and therapies shown or described in this publication will do this at their own risk. Because of rapid advances in the medical sience, IF recommends that independent verification of diagnosis, therapies, drugs, dosages and operation methods should be made before any action is taken.
Although all advertising material which may be inserted into the work is expected to conform to ethical (medical) standards, inclusion in this publication does not constitute a guarantee or endorsement by the publisher regarding quality or value of such product or of the claims made of it by its manufacturer.

Legal restrictions
This work was produced by IF Publishing, Munich, Germany. All rights reserved by IF Publishing. This publication including all parts thereof, is legally protected by copyright. Any use, exploitation or commercialization outside the narrow limits set forth by copyright legislation and the restrictions on use laid out below, without the publisher's consent, is illegal and liable to prosecution. This applies in particular to photostat reproduction, copying, scanning or duplication of any kind, translation, preparation of microfilms, electronic data processing, and storage such as making this publication available on Intranet or Internet.
Some of the products, names, instruments, treatments, logos, designs, etc. reffered to in this publication are also protected by patents and trademarks or by other intellectual property protection laws« (eg. «IF«, «IIF« and the IF-Logo) are registered trademarks even though specific reference to this fact is not always made in the text.
Therefore, the appearance of a name, instrument, etc. without designation as proprietary is not to be construed as a representation by publisher that it is in the public domain.
Institutions' subscriptions allow to reproduce tables of content or prepare lists of Articles including abstracts for internal circulation within the institutions concerned. Permission of the publisher is required for all other derivative works, including compilations and translations. Permission of the publisher is required to store or use electronically any material contained in this journal, including any article or part of an article. For inquiries contact the publisher at the adress indicated.

The Foundation of Knowledge

Multi-unit connection for the Strategic Implant®: an innovative way for achieving retrievability of prosthetics on fully polished single piece implants used in an immediate loading protocol.

Authors
Dr. Vivek Gaur
Dr. Anita Doshi
Dr. Stefan Ihde
Dr. Antonina Ihde
Dr. Lukas Palka

Abstract
The concept of Strategic Implant® is well proven by long-term results that were acquired with scientific methods. The concept allows treatment of cases with mild to severe atrophy, as well as all other standard cases.

From the field of 2-stage-implants we know, that some practitioners tend to use screw connection between the implants and the prosthetic restoration. Since rough conventional dental implants show a high complication rate and frequently peri-implantitis makes it necessary to remove prosthetics and single affected implants, the treatment providers hope that if the prosthetic restoration can be removed, it can be adjusted in the dental

laboratory and prolong its potential period of usage.

BECES® MU gives this additional feature of retrievability. The aim of this paper was to pinpoint clinical steps for delivering a screw-retained restoration on Strategic Implant®: the impression-taking procedure using open-tray technique and final delivery of the prosthesis, has been presented in a step-by-step manner illustrated by detailed photographs. Furthermore, advantages and disadvantages of screw-retained restorations have been discussed and compared to treatments with cemented restorations.

Key Words
Strategic Implant®;
Immediate Functional Loading;
Single-Piece Dental Implants;
Cortical Implantology;
Multi-Unit Abutment

Introduction

The concept of Strategic Implant® (corticobasal implantology) is a well documented, simple and effective procedure, which leads to excellent results [1-3]. In contrast to conventional implants, corticobasal implants are fully polished and designed for fixation in the basal bone, especially in the cortical bone. This technology works in a different manner compared to conventional implant systems with their conventional technology [4]. In corticobasal implants their load transmitting threads are anchored in native, residual, cortical bone areas, often far from the actual clinical tooth, i.e. distant in a vertical and/or sagittal and/or horizontal direction [5]. In order to allow for the connection between the prosthetic restorations and the single piece implants, shafts are angulated (parallelized) by bending. This allows placement and usage of implants even in those cases, where vertical bone supply is reduced, such as moderate to severe or even ultimately resorbed ridges. Due to the bendability of the implant, even very remote bone areas can be reached and used for anchorage. Application of Strategic implant® concept, not only avoids any additional surgical procedures, but also provides reliable anchorage in cortical bone even in severely reduced vertical bone heights. Moreover, it can (and actually must) be loaded immediately without

any waiting period. The technology of Strategic Implant® is modern and utilizes stable cortical portions of the jawbones for retention of the dental implants. "Bicortical" and other corticobasal implants had been available on the market for decades, but only over last few years the concept has been developed and described in full, and the methods of application of these implants have been standardized [6]. Cortical bone provides excellent quality for retention of these unique and highly advanced implants. Dental implantology with Strategic Implant® follows the application of the rules of orthopedic surgery [3].

During the lifespan of implant prosthesis, the clinician may wish to remove the restoration in order to modify the design or repair ceramic fractures. While screw-retained designs make all of these modifications possible with ease, in case of cemented one the restoration itself may be destroyed during the removal procedure if the cement seal cannot be broken easily. Multi-unit abutments offer a powerful, component based protocol to standardize the necessary angle, position and level for the prosthetic platform. The ability to obtain a common restorative platform and harmonious path of insertion across multiple implants, frees laboratories from the complications which may be imposed by divergent implant placement.

The aim of this article is to describe the clinical application and protocol of a smooth surfaced, one-piece implant (BECES® MU), which is cortically anchored and used in immediate loading protocol. The MU abutment head is manufactured pre-angulated (degrees) and the inserting tool achieves traction by connecting to parallel surfaces above and below the equator of the abutment head. The implant neck is nevertheless bendable just as the traditional BECES® implants for cemented connection to prosthetics. This article reports on successful clinical cases of immediate functional loading of BECES® MU implants with screw-retained prosthesis, without any sinus lifts nor bone augmentations and without the risk of developing peri-implantitis [7].

Case reports

Case 1

A 65-year-old, healthy female patient with a fully edentulous upper arch and multiple missing lower teeth presented to the clinic with a desire to have fixed restored teeth. Clinical examination (Fig. 1, 2, 3) revealed fully edentulous maxillary arch and multiple missing teeth in the mandibular arch. The patient had a panoramic overview picture (OPG) taken before extractions of the maxillary teeth (Fig. 4). After discussing the various treatment options and upon

obtaining the informed consent from the patient, a decision was made to use a single-piece immediate loading smooth surface bi-cortical screw implants with multi unit abutment and screw retained prosthesis in the maxillary arch (Fig. 5) and mandibular teeth to be replaced by crown and bridge on natural teeth except 46 which was replaced by 2 KOS implants with cement retained crown.

Fig. 1: *Clinical intra-oral examination (maxillary arch).*

Fig. 2: *Clinical intra-oral examination (mandibular arch).*

Fig. 3: *Clinical intra-oral examination.*

Fig. 4: *Radiographic pre-operative view.*

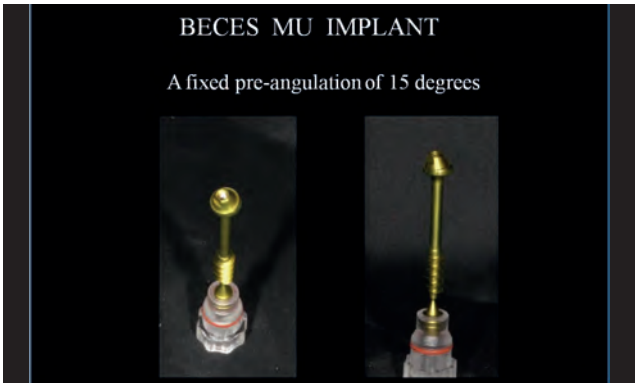

Fig. 5: *BECES® MU (single piece multi-unit) implant on the delivery handle.*

Local anesthesia was achieved with Lidocaine 2% with adrenaline 1:100000. Infiltration was made in the area of the greater palatine nerve, the soft palate and the whole buccal mucosa plus the incisal foramen. Following soft tissue disinfection with 5% Betadine solution (water based), the preparation of osteotomy sites was carried out flaplessly using the sequential order of calibrated drills (BCD, Twist Drill 2.0) as recommended by the manufacturer (Simpladent GmbH, CH-8737 Gommiswald, Switzerland). The sites were cooled with saline solution in external mode while a drill speed of 27.000 rpm was applied. For the distal maxilla the straight handpiece (1:1) with a 40mm twist drill was used, whereas for the anterior sites angled handpieces 1:1 were applied.

The BECES® MU provides a fixed pre-angulation of 15 degrees. A special insertion tool is required for the placement of those implants. This screw retained insertion tool is fixed to the implant with the help of hex driver (Fig. 6). Implants can be bent after insertion by just using the insertion tool. The implant with the connected insertion tool fits onto the regular implant adapter (Fig. 7), which is connected to the hand grip. Therefore, insertion tool, hex driver and adapter for implant are needed to place implants successfully (Fig. 8).

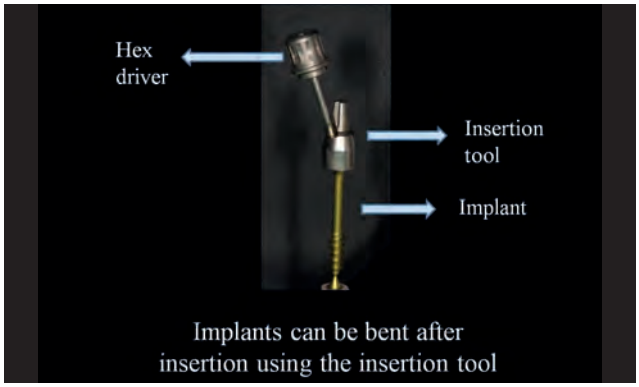

Fig. 6: *BECES® MU with insertion tool tightened with hex driver.*



Fig. 7: *BECES® MU with insertion tool in hand grip adapter.*



Fig. 8: *An instrument for BECES® MU placement.*

As the patient had an existing denture, it was used to create a stent/guide to control the bending of implants to achieve good esthetic results (Fig. 9). In the distal maxilla two one-piece implants with a diameter of 3.6 mm and a length of 29 mm and 14 mm respectively were placed on one side, with one of them being anchored in the cortical of the pterygoid plate (of the sphenoid bone) and one anteriorly to it in the palatal bone on the right side, where also superior primary stability was achieved. Implants with the length of 26mm and 23mm were placed and anchored in the distal maxilla on the left side, with one implant anchored in the pterygoid process of the sphenoid bone and one anteriorly to it in the palatal bone.

Fig. 9: *A stent to check bending of implants.*

It is advisable to keep the insertion tool on the first placed implant while placing the second one to know the direction of the endossous part and to avoid both implants touching. On the right side (Fig. 10) the screw access hole had been positioned distally and on the left side (Fig. 11) - palatally. The palatal access hole allowed for easier prosthetic work, both placement and removal of screw became easier.

Four anterior implants of 3.6 mm in diameter and 17 mm long were placed engaging nasal cortical plate and one implant of 3.6/23 mm distally on each side engaging the nasal buttress area.

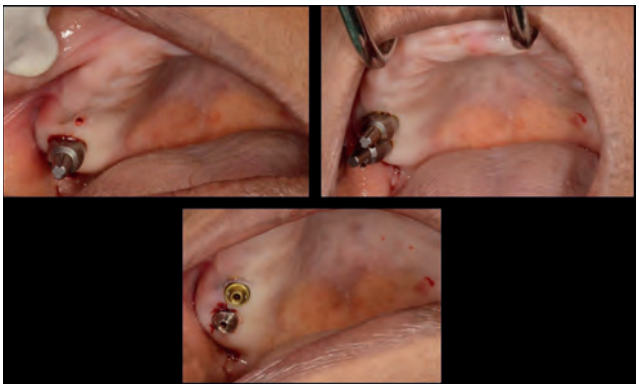

Fig. 10: *Placement of pterygoid implants on the right.*

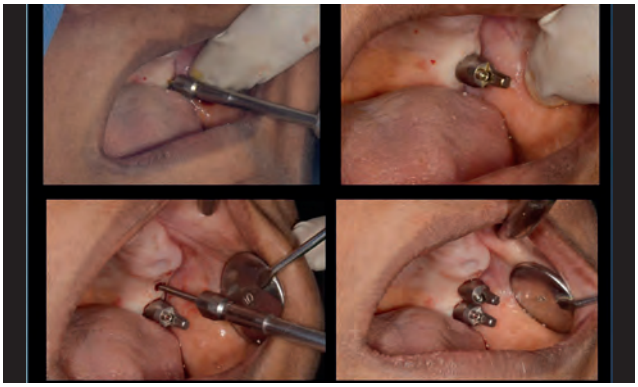

Fig. 11: *Placement of pterygoid implants on the left.*

Since insertion tools are utilized also for bending the shafts of the implants, an early removal before at least equipping a full section of the jaw with implants and bending them, is not advisable (Fig. 12). It is very important to bend anterior implants for esthetic reason in a favorable position of the internal thread so that screw access holes will be positioned on the palatal side of the front teeth (Fig 13). A stent can be useful for confirming the position of the access hole (Fig. 14).

Fig. 12: *Bending of anterior implants.*

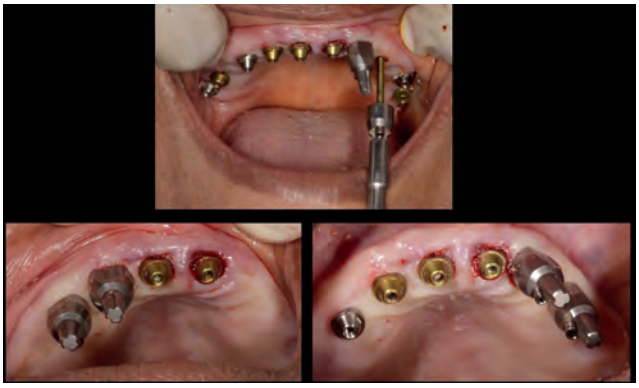

Fig. 13: *Placement of anterior implants.*

Fig. 14: *Implants positions were verified using the stent.*

In total 10 BECES® MU implants were placed in maxillary arch (Fig. 15) and 2 KOS MU in distal right mandible (Fig. 16). A post-operative panoramic overview picture was taken. Immediately after surgery final impression was taken for final prosthesis (Fig 17).

1. Impression Coping Open Tray Multi-unit was connected on BECES® MU and tightened using the hex Screwdriver (Fig. 18).
2. The copings were then splinted with a self-polymerizing resin (Fig. 19). This ensured an accurate transfer without accidental displacement of the impression copings.
3. A prefabricated impression tray was used in this case (Fig. 20). It is possible to perforate the impression tray at the dental chair side to allow full seating of

the tray and compensate the protrusion of impression transfers

4. Light body impression material was injected around implants and the tray filled with putty impression material (rigid polyvinyl siloxane) was seated fully so that the tips of all the impression transfers were located. Excess impression material was removed from the access holes of the transfers.
5. After setting of the silicone, the transfers were unscrewed and the impression tray was removed (Fig. 21).
6. Impression posts were connected with implant analogs and proper seating of the components was verified for each implant.
7. The silicone gingival mask (for the model) (Gingitech, Ivoclar/Vivadent, FL - Schaan, Liehtenstein) was filled into the tray (Fig. 22). Since the silicone tends to adhere to the PVS impression material, a thin layer of silicone separator was applied over the inside of the impression first.. The material should fully cover the prosthetic connection and reach just slightly apically to the top of the implant analog. Too much gingival mask should be avoided, because it may later become unstable on the cast.
8. Cast was poured with dental stone and trimmed (Fig. 23).

Fig. 15: *Immediate post operative view (maxillary arch).*

Fig. 16: *Immediate post operative view(mandibular arch).*

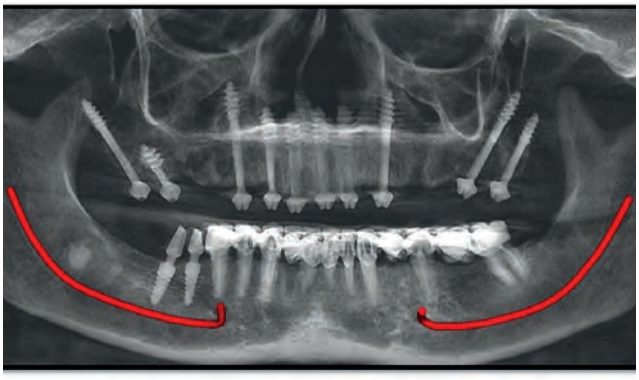

Fig. 17: *Immediate post operative OPG.*

Fig. 18: *With open tray impression posts.*

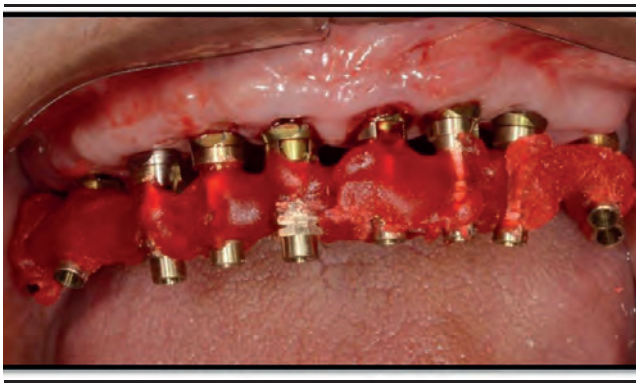

Fig. 19: *Splinting impression post with pattern resin.*

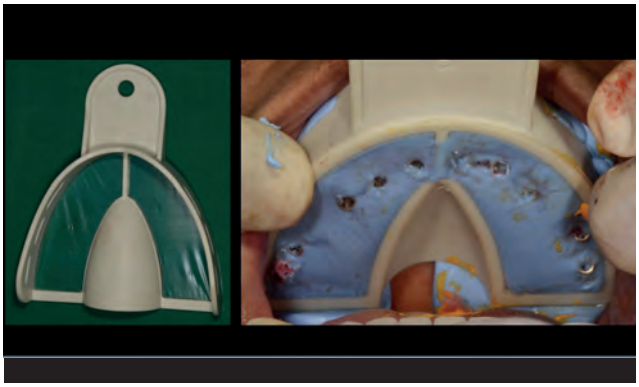

Fig. 20: *Open tray impression.*

Fig. 21: *Final impression.*

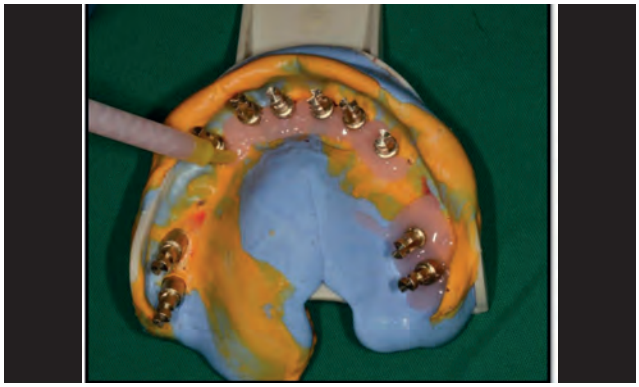

Fig. 22: *Making gingival mask.*

Fig. 23: *Final cast.*

For jaw relation indexing of the denture the impression material (i.e. Polyvinylsiloxane [PVS]) was used. Adequate space was created with an acrylic bur in the denture where index markings were present.

Two temporary cylinders were picked up in the denture with acrylic resin and screw retained in mouth so that it was stable during recording of jaw relation (Fig- 24). The final bite was taken with bite registration paste (Fig. 25). The bite had been inspected before and it was found that the occlusal centric and the joint centric were identical [8] justifying the simplified procedure of bite taking.

Fig. 24: *Indexing of denture and pick up of titanium cylinder.*

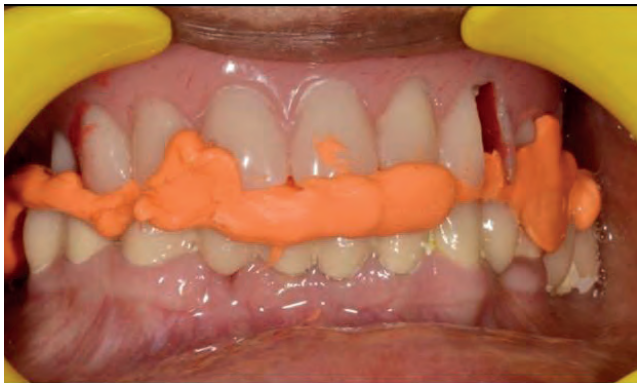

Fig. 25: *Recording aw relation.*

There are two types of castable abutments that may be used in the laboratory:

- One fits on the T-Base (the T-Base is cemented into the bridge and later screwed from coronal onto the implant as seen in Fig. 26; the "castable abutment" becomes part of the bridge; this variant was in this case).
- The other variant is the direct usage of a burnout-piece on the implant (utilizing a prosthetic screw only) without T-Base.

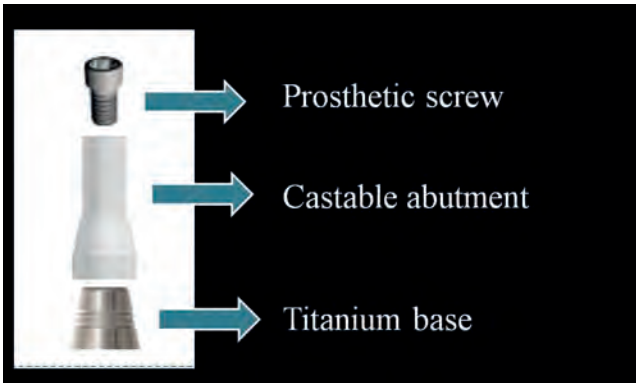

Fig. 26: *Castable abutment on T-base.*

It is advisable to use castable abutments on T-Base, as they are cemented into the final prosthesis while they are on the implant, so any minor inaccuracy in the casting can be compensated and the prosthesis will be absolutely passive. Modern production methods (designing the frames on the computer screen after scanning intra-orally or on the model; laser-printing of the metal frame) provide high accuracy frames and this eliminates the need for the usage of the T-Base.

The bridges were waxed-up on the T-Base using the prefabricated castable abutment and they were then casted (Fig. 27). Excellent healing of the mucosa was noticed around the implants after 24 hours (Fig. 28). T-Bases were screwed on the implants before the metal try-in (Fig. 29). Once the metal was approved and the bite controlled (Fig. 30), final ceramic build-up was done. After the porcelain fused to ceramic, the circular bridge is ready; T-Bases are picked up and cemented/glued into the prosthesis. It can be either done on cast (if the fitting is passive during the trials) or T-Bases can be picked up intra-orally. In this case we have done pick up of T-Bases on the cast; intra oral pick up can be done similarly which we will discuss in another case[1].

Fig. 27: *Wax pattern.*

Fig. 28: *Healing after 24 Hours.*

1 If the pick-up of the T-Base is done in the mouth, the well known problems with excessive cements and the difficulties of their removal are again found in MU implants.

Fig. 29: *T-bases screwed on to BECES® MU implant before metal try- in.*

Fig. 30: *Metal try- in.*

Crestal screw holes of T-Bases are blocked with wax (Fig. 31) so that cement do not flow and block the screw channel. Bonding agent was applied to T-Bases and resin cement was mixed and administered into the final prosthesis. Then this prosthesis is fitted on the T-Bases. Once the resin cement is set, wax was removed and all screws were unlocked. This way all T-Bases were cemented in final prosthesis (Fig. 32). Excess cement was removed and final polishing was done. Fig. s 33 to 35 shows the inner surface of final prosthesis shows T-Base and holes at occlusal and palatal sides are preserved open for screwing and unscrewing of prosthesis.

Fig. 31: *Blocking screw holes with wax before T-base pick up in final prosthesis.*

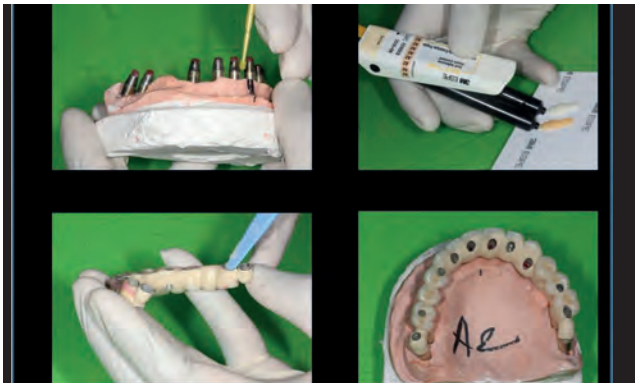

Fig. 32: *Pick up of T-base in final prosthesis.*

Fig. 33: *Final prosthesis.*

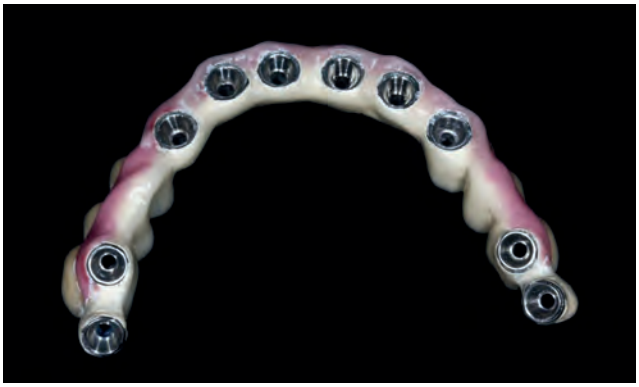

Fig. 34: *Final prosthesis.*

Fig. 35: *Final prosthesis.*

Final screw-connection of prosthesis was done in mouth with 20-25Ncm force (Fig. 36). Access holes were blocked with Teflon (Fig. 37) and then covered with composite material (Figs 38, 39). Finally the occlusion was adjusted so that AFMP angle and chewing table are symmetrical (Fig. 40). Anterior teeth were kept without any contacts (Fig. 41). A very good result was achieved, and the patient was highly satisfied (Fig. 42). A post-operative OPG was taken to check the fit of prosthesis, Fig. 43. The patient was seen for control every month for the first 6 months, with special care paid to the occlusion. Thereafter, the patient was followed up on every 6 months clinical and radiographic check-ups. One year follow up clinical picture and OPG shows excellent result of this procedure, Fig. 44.

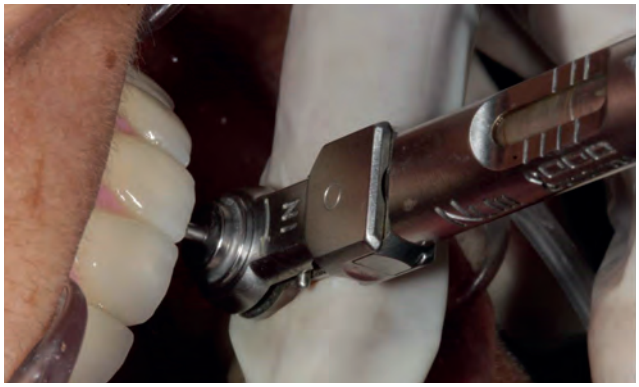

Fig. 36: *Final screw tightening.*

Fig. 37: *Sealing screw access holes with teflon.*

Fig. 38: *Post-operative view (maxillary arch).*

Fig. 39: *Post-operative view (mandibular arch).*

Fig. 40: *Post-operative view.*

Fig. 41: *No anterior contacts.*

Fig. 42: *Post-operative smile.*

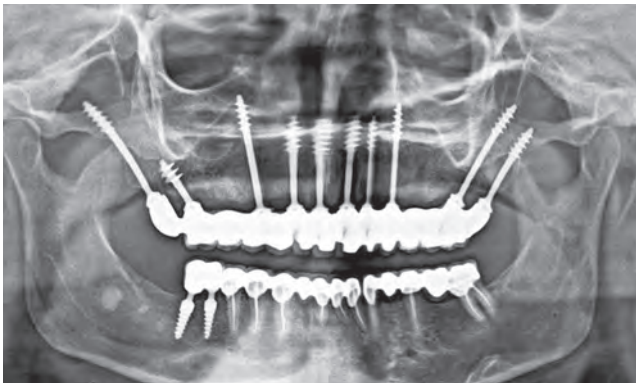

Fig. 43: *Post-operative OPG.*

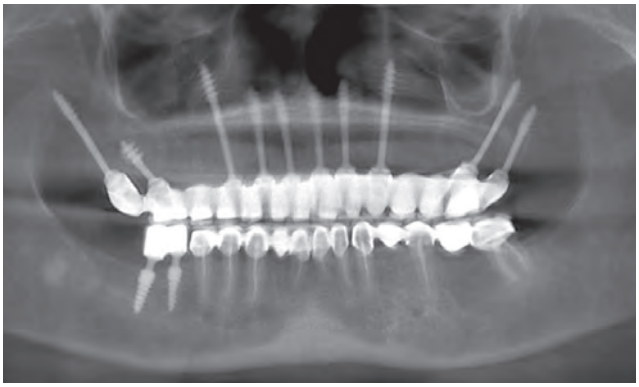

Fig. 44: *1- year follow- up OPG.*

Case 2

A 65-year-old, healthy female patient came to the clinic with a desire to have fixed restored teeth. Clinical examination (Fig. 45, 46) revealed fully edentulous maxillary and mandibular arch. The radiographic examination (Fig. 47) subsequently revealed a heavier atrophy of both arches. After discussing the various treatment plan options and upon obtaining the informed consent of the patient, a decision was made to use single-piece immediate loading smooth surface bi-cortical screw implants with multi unit abutment with screw retained prosthesis. Following same protocol for surgery like in case 1, 10 maxillary and 8 mandibular BECES® MU were placed (Fig. 48, 49).

Fig. 45: *Clinical intra-oral examination (maxillary arch).*

Fig. 46: *Clinical intra-oral examination (mandibular arch).*

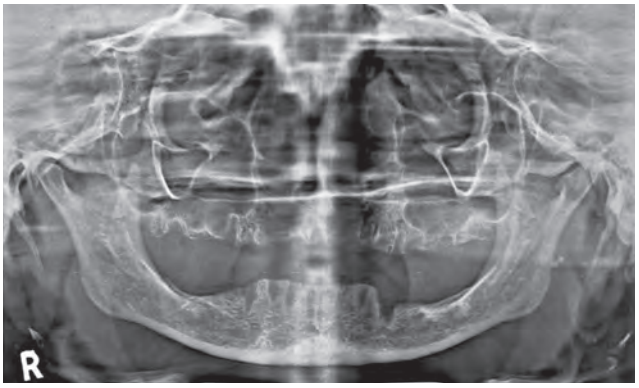

Fig. 47: *Radiographic pre-operative view.*

Fig. 48: *Immediate post-operative view (maxillary arch).*

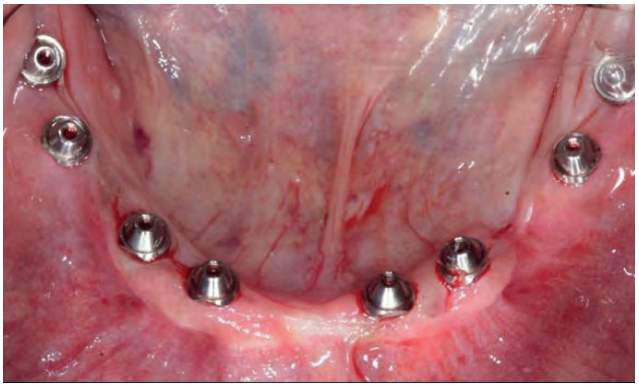

Fig. 49: *Immediate post-operative view (mandibular arch).*

-In mandibular arch care should be taken that screw access holes comes lingually for esthetic reason (Fig. 50)

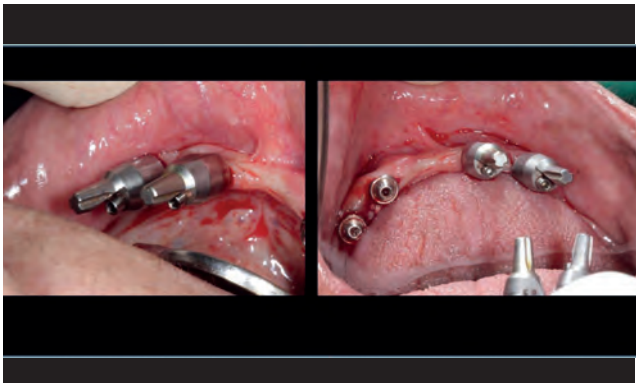

Fig. 50: *Access hole opening should come lingually.*

In mandible implants can be bent in mesio distal (Fig. 51) as well as bucco lingual direction (Fig. 52) using insertion tool so that screw access holes come in favorable direction i.e. lingually in mandibular anterior region and occlusaly in posterior region. If bending of implant is not done properly at this stage esthetic compromised can happen as well as prosthetic difficulty can be encountered.

Fig. 51: *Bending of implants in mesiodistal direction.*

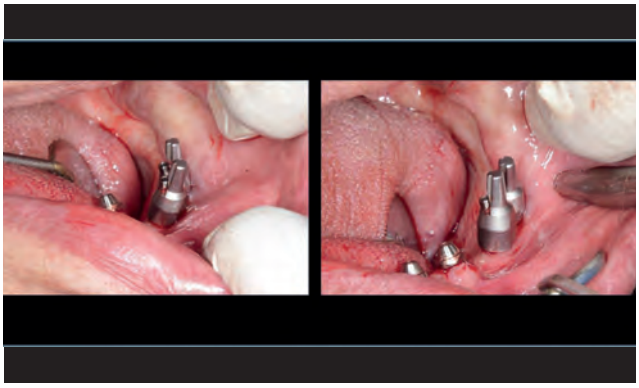

Fig. 52: *Bending of implants in buccolingual direction.*

Post operative OPG was taken immediately after surgery (Fig. 53). Open tray multi-unit impression copings were placed onto the BECES® MU implants, which were then splinted with a low shrinkage self polymerizing resin (Fig. 54 and 55) and open tray impression was taken similar to case 1.

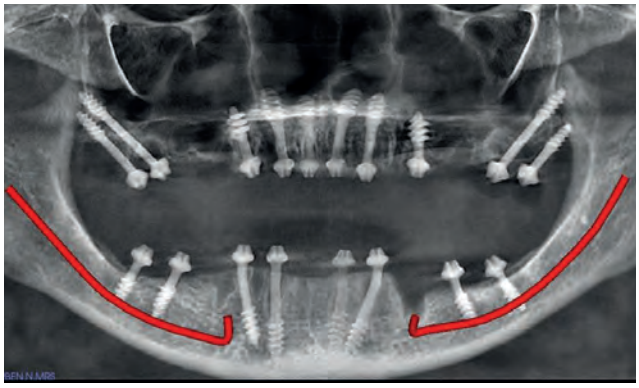

Fig. 53: *Post-operative OPG.*

Fig. 54: *Splinting maxillary impression post with pattern resin.*

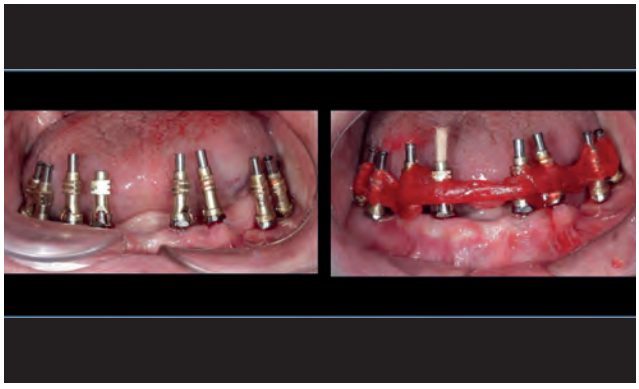

Fig. 55: *Splinting mandibular impression post with pattern resin.*

For jaw relation in this case we fabricated screw retain wax rims by incorporating 2two temporary cylinders in wax rims so that they remain absolutely stable for accurate jaw relation record (Fig. 56).

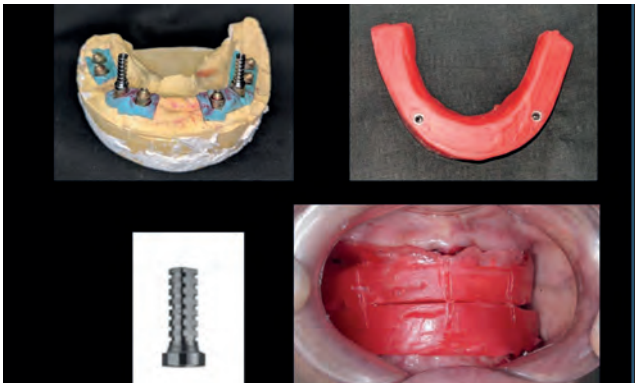

Fig. 56: *Screw retained wax rims for more stabilization during recording jaw relation.*

Later on within 72 hours final metal fused to ceramic prosthesis were screwed in onto the implants similar to case 1 (Fig. 57). Immediate post operative OPG (Fig. 58) and one year post operative OPG (Fig. 59) shows excellent result of this procedure.

Fig. 57: *Post-operative view.*

Fig. 58: *Post-operative OPG after insertion of prosthesis.*

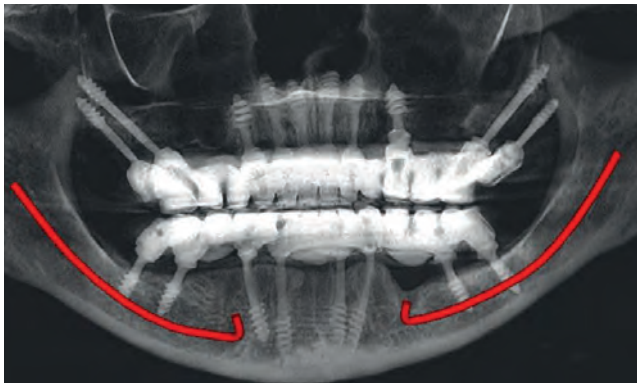

Fig. 59: *One- year post-operative OPG.*

Case 3

A 50-year-old, healthy female patient with bilaterally missing upper posterior teeth presented to the clinic with a chief complaint of difficulty in chewing and a desire to have fixed restored teeth for the same.

Clinical examination (Fig. 60) revealed bilaterally missing premolars and molars in the maxillary arch. Radiographic examination (Fig. 61) revealed severely atrophic posterior maxillae and increased pneumatization of the maxillary sinus. The decision was made to use a single-piece immediate loading smooth surface bicortical screw implants with multiunit abutment with screw retained prosthesis.

Following same protocol for surgery like in case 1 two long one-piece implants with a diameter of 3.6mmand a length of 23mm and 29 mm were placed and anchored in the cortical in pterygoid plate of the sphenoid bone on the right side, where superior primary stability is achievable. Implants with the length of 26mm and 23mm were placed and anchored in the distal maxilla in the left side of the patient, with one implant being anchored in the pterygoid process of the sphenoid bone. The more anterior distal implant reached through the palatal side of the alveolar bone of the maxilla up to the cortical of the nose.

Anteriorly, in the premolar area, two long single-piece implants with a diameter of 3.6mm and a length of 17mm and 14mm were placed and anchored in anterior wall of sinus and canine buttress area on both sides (Fig. 62 and 63).

Fig. 60: *Pre-operative view.*

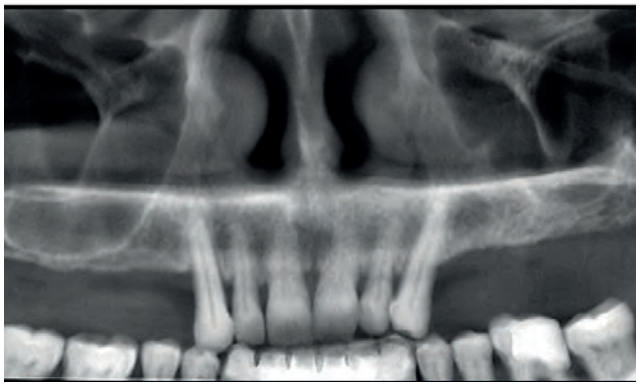

Fig. 61: *Radiographic pre-operative view.*

Fig. 62: *Implant placement.*

The implants were bent to a favorable position of the internal thread so that screw access holes come occlusally. Impression was taken after splinting of impression posts and all the steps were followed till the final sealing of restoration with composite similar to case 1 (Fig. 66 and 67). 6 months post operative OPG (Fig. 68) shows real strategic implantology.

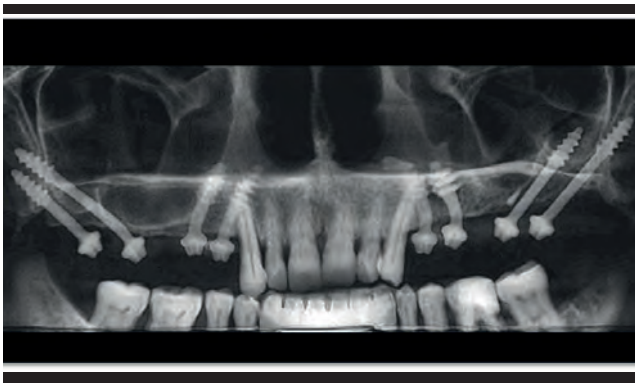

Fig. 63: *Post-operative OPG.*

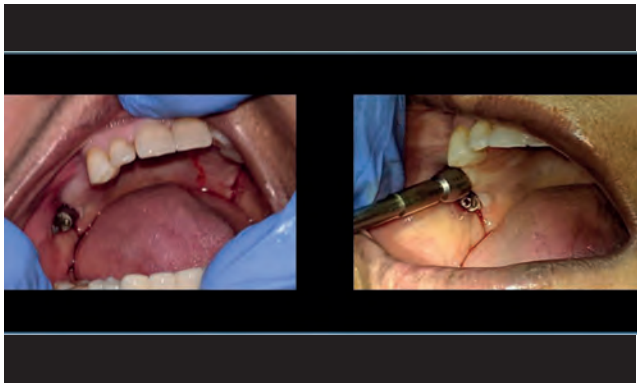

Fig. 64: *To place double pterygoid implant the insertion tool from first pterygoid needs to be removed.*

- To place double pterygoid in some cases insertion tool from first pterygoid needs to be removed especially if there is lack of space between the abutments (Fig. 64)
- Bending can be challenging in segment due to adjacent teeth and bulky adapter so this needs to be taken in consideration while planning a case (Fig. 65)

Fig. 65: *Bending can be challenging in segment due to adjacent teeth and bulky adapter.*

Fig. 66: *Prosthesis screwed on the BECES® MU implants.*

Fig. 67: *Post- operative view.*

Fig. 68: *Six- month follow- up OPG.*

Case 4

A 65-year-old, healthy female patient with a fully edentulous lower arch presented to the clinic with a desire to have fixed restored teeth for the same. Clinical examination (Fig. 69) revealed fully edentulous mandibular arch and maxillary arch that was restored with crowns and bridge. Radiographic examination (Fig. 70) revealed an atrophic mandibular arch. After discussing the various treatment plan options and upon obtaining the informed consent of the patient, a decision was made to use single-piece immediate loading smooth surface bi-cortical screw implants with multi unit abutment with screw retained prosthesis. Eight BECES® MU implants were placed following the surgical protocol described in case 1. The implants were bent to a favorable position of the internal thread with an angulation adapter so that the screw access holes faced occlusally (Fig. 71, 72, 72a).

Fig. 69: *Clinical intra-oral examination.*

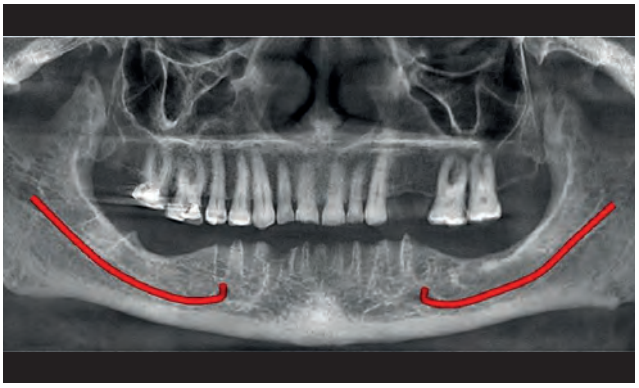

Fig. 70: *Radiographic pre-operative view.*

Fig. 71: *Implant placement.*

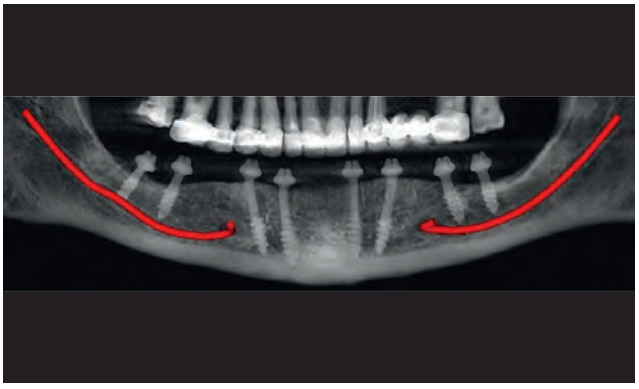

Fig. 72: *Radiographic view post- implant placement.*

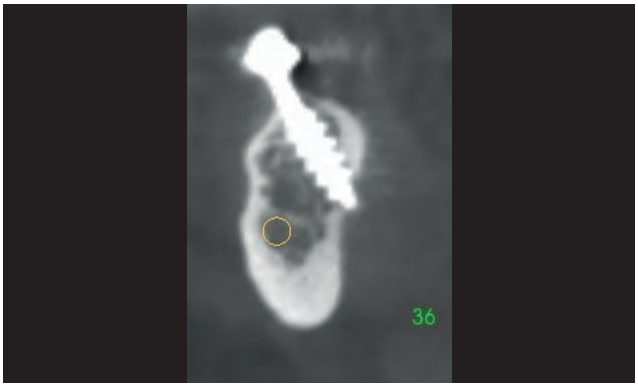

Fig. 72a: *Cross-section showing lingual cortical engagement with BECES® MU implant.*

Immediately post-surgery, the final impression was taken for creating the final prosthesis. Open tray multi-unit impression copings were placed onto the BECES® MU implants (Fig. 73), which were then splinted with a low shrinkage self polymerizing resin (Fig. 74). An open tray final impression (Fig. 75) was made with a rigid polyvinyl siloxane material and final cast was prepared (Fig. 76). In this case we used castable abutment which fits directly on implant (Fig. 77). Castable abutments were screwed on to the implant analogues (Fig. 78) and wax pattern (Fig. 79) was prepared. When using this type of castable abutment laboratory work needs to be really precise as when you use T-base minor errors in casting can be taken care as this T-base are cemented into the prosthesis with cement which

will take care of minor casting shrinkage. Metal try in was done directly on implants (Fig. 80). Final prosthesis screwed on implants with 25Ncm and final sealing was done with Teflon and composite (Fig. 81). Occlusion is adjusted using all principles of strategic implantology (Fig. 82). Postoperative OPG shows excellent fit of prosthesis (Fig. 83).

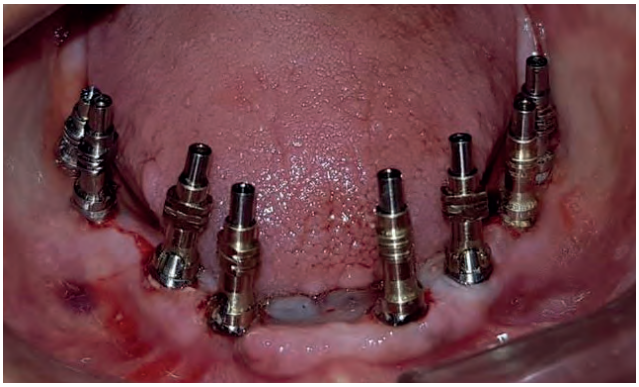

Fig. 73: *Open tray impression post on BECES® MU implant.*

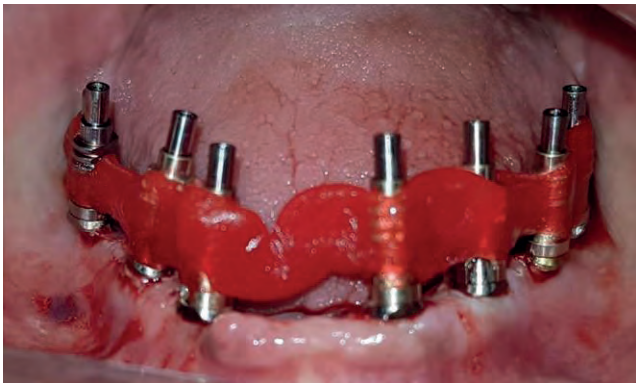

Fig. 74: *Impression post splinted with pattern resin and before pick-up impression.*

Fig. 75: *Final impression.*

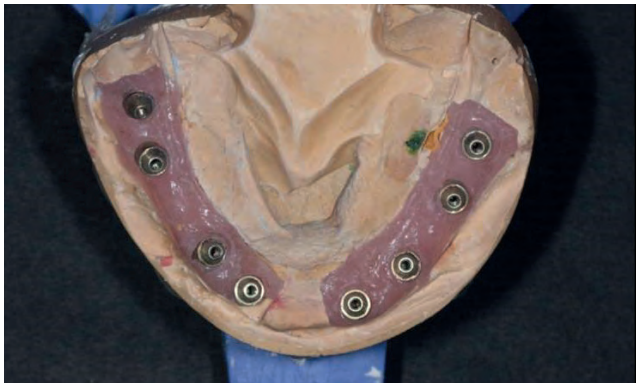

Fig. 76: *Final cast.*

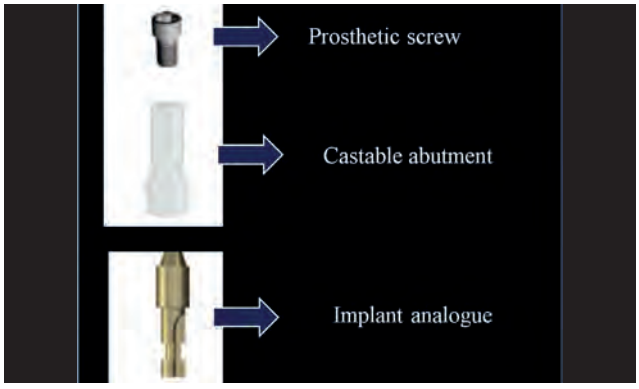

Fig. 77: *Castable abutment which fits directly on implant (no t-base).*

Fig. 78: *Castable abutment screwed on an implant analogue.*

Fig. 79: *Wax pattern fabrication.*

Fig. 80: *Metal try- in.*

Fig. 81: *Sealing of screw access holes with Teflon® and composite.*

Fig. 82: *Final post operative view.*

Fig. 83: *Final post- operative OPG.*

Discussion

The technology of Strategic Implant® is the most patient-friendly and least invasive technique that can be employed to restore normal masticatory function in the edentulous maxillae and mandible. The philosophy of this treatment differs from conventional / alveolar / axial approach in implantology. Implants belonging to Strategic Implant® system are anchored cortically, and the process of creating this anchorage has been denominated as "osseo-fixation". Corticobasal implants show a dual mode of integration, where gradually developing "osseo-integration" follows to the rigid "osseo-fixation" which stabilizes the BIPS[2] from the beginning [9]. Secondary osseo-integration into spongious bone areas through which endosseous parts of the implants are projecting is expected to happen in any case later. However, for primary stability, i.e. for the success of the treatment, the macro-mechanic anchorage ("osseo-fixation") in the 1st, 2nd or 3rd cortical is decisive [10-12].

With the smooth surfaced single-piece corticobasal screw implants (with multiunit abutment) BECES® MU it is possible to restore fully or partially edentulous maxillary or mandibular arches with a final, screw retained prosthesis within very short time.

The most common complication in implant restorations is chipping of the veneering. Literature reports that "chipping off" of ceramic veneering can happen in up to 50% of cases [13]. Therefore, especially if materials like ceramics or zirconium (which cannot be repaired in the mouth) are applied, easy retrievability of the restoration could be an advantage. At the same time some clinicians rise an argument of chipping ceramic during removing of cemented prosthetics forgetting that this can be easily repair in dental lab like in case of screw ones. Due to high precision of modern frameworks, loosening and fracturing of the abutment screw is less frequent today and can be solved by retightening or replacing the screw.

BECES® MU is a single piece multiunit implant thus there is no abutment junction at crestal cortical and no cement junction or no micro movements at crestal cortical, making it unaffected by prosthetic system leading to bone leveling or bone apposition rather than bone resorption at 1st cortical which is common in conventional two piece MU implants.

The choice of a screw-retained versus a cemented restoration is a decision that

2 BIPS: Bone-Implant-Prosthetic-System, see www.implant-foundation.org, consensus documents.

involves several points of consideration. Clinician should be aware of the advantages and disadvantages of using screw-retained and cemented crowns [13-15]. Here are some factors that should be taken into consideration when choosing which type to use:

Retrievability

The main advantage of screw-retained restorations is retrievability. To have the option to easily remove the prosthesis whenever it is required without any damage to the restoration is clearly an advantage. However, also severe disadvantages and risks come with screw -retained prosthesis:

- The prosthetic restorations can become loose on single implants, if the screw fails or gets lost. As a result not all implants participate in the load transmission and some of those implants which still hold the bridge can become mobile. This risk is typically underestimated by conventional implantologists working with already integrated (2-stage) implants. If screws fail on well integrated conventional implants, the implant will be rarely damaged, whereas rather the prosthetic restoration will be damaged or fracture. Likewise, on corticobasal implants for cemented connections (which form initially an elastic BIPS) it is highly advisable to use very strong permanent cements. The situation is different compared to well integrated 2-stage implants [16]
- It is true that under retrievable bridges implants can be removed easily, replacing those implants under the same prosthetic restoration is however impossible. In contrary, corticobasal implants with cementing heads can often be replaced even without removing the prosthetic restoration. In such cases the shaft of the implant is cut off the bridge close to the crown and the endosseous part of the implant is removed. After this (or after soft tissue healing) the cementing hole is opened in occlusal direction and the new drilling for the implant placement is performed with a long 2mm - twist drill and the new implant is inserted through the occlusal hole in the crown.
- Another critical point is the occlusal surface of the bridges which are interrupted by the holes and due to these holes and the material around they becomes vulnerable to fracture. If occlusal contact points are on or nearby those openings, the danger of damage to the veneers is considerable. Hence the “advantage” of retrievability turns often out to be the cause of problems, which are then solved by retrieving the restorations.

Hygiene

- Excess cement left behind cemented restoration can create infections and subsequent bone loss. While the polished shaft of the implants prevents peri-implantitis, remnants of cement will destroy this advantage and cause peri-mucosal or peri-implant infections [17]. The literature shows that the soft tissue surrounding screw-retained crowns are healthier than the peri-implant mucosa surrounding cemented restorations [18], provided however, that the implant-abutment connection is positioned well above the mucosa line.
- The only possibility to avoid damages done through cement remains is to remove them. If bridges are cemented, especially after tooth extractions and flap preparations, separate appointments for a search for cements after soft tissue healing should be planned. Rarely some patients can show reactions and transient pain after their mucosa has been exposed to (non-set) cements.
- "Retrievability" does not mean that the patient can take the bridge out for daily cleaning. The difference between the possibility of removal of the bridge by the dentist and removal by the patient (e.g. every) day must be explained. The patients would according to our experience rather expect the word "removable" allows them to remove the restoration. Today "removable teeth" are practically never chosen by the informed patient, the clear trend in the population goes towards "fixed teeth". Note that it is possible to fabricate retentive bars on the Strategic Implant® and to cement them on the implant`s heads, while the denture itself is removable.

Esthetics

One major disadvantage inherent in the screw-retained system is the need for an access hole. In cases where the implant can be placed in an ideal prosthetically-driven way, access holes are positioned in the middle of the occlusal surface in the posterior areas, and in the palatal concavity in the front tooth region. Screw heads are first protected with Teflon tape, and then the access hole is filled with composite. From a technical point of view, good stability can be achieved, and since the composite filling is located at an aesthetically uncritical region, patient acceptance is very high. If a re-intervention is required, quick and non-destructive access to the screw is easy to achieve. But in many situations if implants were not bended to ideal position than the screw hole in prosthesis may compromise esthetic, occlusion, and

porcelain strength [14], especially if the diameter of the screw was wide. The cemented restorations obviously have no entrance cavity. All-ceramic screw-retained crowns reduce the challenge of masking underlying discoloration from showing through the occlusal access opening once it is sealed by resin cement.

Implant inclination

Particularly, when screw-retained restorations are planned to be the prosthetic choice, surgeon should bring to the attention the inclination of the implant accordingly while planning the surgical procedure. Pterygoid and posterior implants screw access holes should be kept lingually rather than distally for ease of screw tightening and removing. Also in anterior teeth the implant needs to be inclined lingually to allow screw emergence through the cingulum area of the restoration.

Accessibility

Placing a screw-retained restoration in a patient with a limitation in opening the mouth can be challenging if there was not sufficient space for the screw-driver to be inserted [19, 20], xxii.

Screw loosening

Screw-retained restorations are associated with screw loosening complication especially in single crown restoration. The frequency of loosening of the prosthetic screw is reported to be between 5% and 65% [20-22]. Using a mechanical torque instrument to tighten the screw to a recommended torque level (25 Ncm) can reduce the incidence of this severe prosthetic complication, especially if the screws are re-tightened several times after the initial placement of the bridges [23, 24]. This requires however separate appointments and burdens of traveling for the patient.

Compensation of vertical bone loss as a result of remodeling and atrophy

In cases with multiple extractions in the esthetic zone we often observe larger gaps between the bridges and the gums. If implant with heads for cementations are used, the gap is corrected by a 2nd bridge, simply by positioning “B21”-abutments on the shafts after removing the abutment head or parts of it. The same option is given for MU-implants; however, due to the design of the MU-head, a “B21-Variant” of an MU head cannot be produced. This means that in such cases, - and with the help of B21-abutments which change the MU-Implant into a cemented variant we

can solve the problem, but (unless all implants are altered), on some of them the bridge will be cemented, on others it will be screwed, which seems illogical. From this point of view the usage of the MU-variant to the Strategic Implant® should be considered only for cases where considerable atrophy is present before treatment start (and where hence not a lot more atrophy is expected to happen).

Conclusions

Korsh and Walter compared the frequency of loosening of implant-supported screw-retained fixed dental prostheses with cemented fixed dental prostheses and they came into conclusion that over a period of 3.5 years from implant placement the number of loosened screw-retained prostheses was almost three times greater than cement-retained prostheses (29.3% vs. 10%, respectively) [25]. What is more, they also found out that screw-retained prostheses cause more technical complications, e.g. loosening of the whole restoration. Also Nissan et al. reported more frequent abutment screw loosening in screw-retained restorations than in cemented ones (32% to 9%, respectively) with additional conclusion that cement-retained prostheses have better results in terms of biological parameters, i.e. marginal bone loss and gingival index [26]. Sinjari et al. studied 300 single implant-supported crowns with either screw-retained or cement-retained abutments and concluded that MBL was significantly greater for the first group than for the latter [27]. Lemos et al. investigated MBL in screw versus cement-retained prostheses and reported less MBL over 12 and 180 months in cement-retained fixed implant-supported restorations, as well as fewer prosthetic complications, and higher implant survival rates [28]. Moreover, Tonella et al. suggested that stress is better distributed and lower in cemented prostheses [29].

In their systematic review Jain and colleagues pointed out that the retention failure rate in studies shorter than 5 years was from 0% to 15.74% for cement-retained restorations and from 0% to 46.66% for screw-retained, whereas in longer studies (>5 years) it ranged from 0% to 23.72% and 0% to 50%, respectively [30]. Moreover, they report greater number of failures in screw-retained prostheses including fatigue; inadequate tightening torque and fit, poorly machined components, vibrating micro movement, and excessive loading [30].

One of the most frequently mentioned disadvantage of cement- retained restorations is the excess cement and subse-

quent peri-implant infections, however, only recently researchers have suggested that this may depend on the type of cement used [25] rather than the type of retention.

Strategic Implant® is available in two different connection designs: traditionally cemented connections -and multi-unit. Both treatment options can are highly predictable and have their own advantages and disadvantages. The decision for one variant is guided by the following considerations: retrievability, the possibility (or the unfortunate necessity) of re-tightening of screws, and the risk of not leaving residual cement below the gum line are the main advantages of screw-retained restorations. If ceramics or zirconium are used for veneering the screw holes are the areas of significant weakness for the veneering, as chip off is frequent. While improved esthetic outcome and better occlusion and ease of impression taking are the main advantages of cemented restorations, their main disadvantage is difficulty of removal. The necessity for removal of prosthetic restorations is however strongly reduced, if the veneering is made from composite (e.g. metal-to-composite bridges), because these veneers can be repaired easily with bonding and composite, which means are available in every dentists office around the world. Considerations regarding problems which stem from gaps developing under bridges after their incorporation may indicate that MU-variants of Strategic Implant® could be used in cases of mild and severe atrophy.

References

1. Lazarov A. Immediate Functional Loading: Results for the concept of the Strategic Implant®. Ann Maxillofac Surg 2019; 9: 78-88.
2. Dobrinin O., Lazarov A., Konstantinovic V., Sipic O., Siljanovski D., Milcic B. et al. Immediate-functional loading concept with one-piece implants in the mandible and maxilla – A multi-center retrospective clinical study; J. Evolution Med. Dent. Sci. 2019; 8 (05): 306-315.
3. Yadav R., Sangur R., Mahajan T., Rajanikant A., Singh N., Singh R. An Alternative to conventional dental implants: basal implants. Rama Univ J Dent Sci. 2015; 2(2):22-28
4. Ihde S. Comparison of basal and crestal implants and their modus of application. Smile Dental Journal 2009;4:36-46.
5. Goldmann T., Ihde S., Kuzelka J., Himmlova L. Bendable vs. angulated dental implants: consideration of elastic and plastic material properties based on experimental implant material data and FEA Biomed Pap Med Fac Univ Palacky Olomouc Czech Repub. 2008; 152(2):1.
6. International Implant Foundation: Consensus on 16 methods for the placement of basal implants: http://implantfoundation.org/en/consensus-16-approved-methods-2018-menu-en
7. Ihde S, Ihde A. Considerations regarding dental implant surfaces, bone reaction and "peri-implantitis". Ann Maxillofac Surg 2018; 8: 365–368
8. Ihde S. Ihde A: Cookbook Mastication, 3rd edition; International Implant Foundation Publishing. 2019.
9. Kuzelka J., Goldmann T., Himmlova L., Ihde S. Modeling of load transmission and distribution of deformation energy before and after healing of basal dental implants in the human mandible. Biomed Tech (Berl). 2011; 56(1): 53-58.
10. Ihde S., Ihde A., Lysenko V., Konstantinovic V., Palka L. New Systematic Terminology of cortical Bone areals for osseo-fixated Implants in Strategic Oral Implantology J.J.Anatomy. 2016; 1(2): 007
11. Donsimoni J., Dohan D. Les implants maxillo-faciaux à plateaux d'assise: Concepts et technologies orthopédiques, réhabilitations maxillo-mandibulaires, reconstructions maxillo-faciales, réhabilitations dentaires partielles, techniques de réintervention, méta-analyse. 1re partie : concepts et technologies orthopédiques. Implantodontie. 2004; 13(1): 13-30.
12. Ihde, S. Principles of BOI, Scientific and Practical Guidelines to 4-D Dental Implantology. Springer, Heidelberg, New York. 2005.
13. Chee W., Felton D., Johnson P., Sullivan D.. Cemented versus screw-retained implant prostheses: Which is better? Int J Oral Maxillofac Implants. 1998;13:352–7.
14. Papaspyridakos P., Chen C., Gallucci G., Doukoudakis A., Weber H., Chronopoulos V. Accuracy of implant impressions for partially and completely edentulous patients: A systematic review. Int J Oral Maxillofac Implants. 2014;29:836–45.
15. Hebel K., Gajjar R.. Cement-retained versus screw-retained implant restorations: Achieving optimal occlusion and esthetics in implant dentistry. J Prosthet Dent. 1997;77:28–35.
16. Sheets J., Wilcox C., Wilwerding T. Cement selection for cement-retained crown technique with dental implants. J Prosthodont. 2008;17:92–6.
17. Goodacre C., Bernal G., Rungcharassaeng K., Kan J. Clinical complications with implants and implant prostheses. J Prosthet Dent. 2003;90:121–32.
18. Weber H., Kim D., Ng M., Hwang J., Fiorellini J.. Peri-implant soft-tissue health surrounding cement-and screw-retained implant restorations: A multi-center, 3-year prospective study. Clin Oral Implants Res. 2006;17:375–9.
19. Chee W., Jivraj S. Impression techniques for implant dentistry. Br Dent J. 2006;201:429–32.
20. Guichet D., Caputo A., Choi H., Sorensen J.. Passivity of fit and marginal opening in screw-or cement-retained implant fixed partial denture designs. Int J Oral Maxillofac Implants. 2000;15:239–46.

21. Jung R., Zembic A., Pjetursson B., Zwahlen M., Thoma D.. Systematic review of the survival rate and the incidence of biological, technical, and aesthetic complications of single crowns on implants reported in longitudinal studies with a mean follow-up of 5 years. Clin Oral Implants Res. 2012;23(Suppl 6):2–21.
22. Pjetursson B., Thoma D., Jung R., Zwahlen M., Zembic A. A systematic review of the survival and complication rates of implant-supported fixed dental prostheses (FDPs) after a mean observation period of at least 5 years. Clin Oral Implants Res. 2012;23(Suppl 6):22–38.
23. Winkler S., Ring K., Ring J., Boberick K.. Implant screw mechanics and the settling effect: Overview. J Oral Implantol. 2003;29:242–5.
24. Siamos G., Winkler S., Boberick K.. Relationship between implant preload and screw loosening on implant-supported prostheses. J Oral Implantol. 2002;28:67–73.
25. Korsch M., Walther W. Retrospective analysis of loosening of cement-retained vs screw-retained fixed implant-supported reconstructions. Quintessence Int. 2015; 46(7), 583-9.
26. Nissan J., Narobai D., Gross O., Ghelfan O., Chaushu G. Long-term outcome of cemented versus screw-retained implant-supported partial restorations. International Journal of Oral and Maxillofacial Implants. 2011; 26(5), 1102- 1107.
27. Sinjari B., D'Addazio G., Traini T., Varvara G., Scarano A., Murmura G., Caputi S. A 10-year retrospective comparative human study on screw-retained versus cemented dental implant abutments. Journal of biological regulators and homeostatic agents. 2019; 33(3), 787-797.
28. Lemos C., de Souza Batista V., de Faria Almeida D., Júnior J., Verri, F., Pellizzer E. Evaluation of cement-retained versus screw-retained implant-supported restorations for marginal bone loss: A systematic review and meta-analysis. J Prosthet Dent. 2016; 115(4), 419-427.
29. Tonella B., Pellizzer E., Ferraço R., Falcón-Antenucci R., Carvalho P., Goiato, M. Photoelastic analysis of cemented or screwed implant-supported prostheses with different prosthetic connections. Journal Oral Implantol. 2011; 37(4), 401-410.
30. Jain J., Sethuraman R., Chauhan S., Javiya P., Srivastava S., Patel R., Bhalani B. Retention failures in cement- and screw-retained fixed restorations on dental implants in partially edentulous arches: A systematic review with meta-analysis. J Indian Prosthodont Soc. 2018; 18(3):201-211.

The Foundation of Knowledge

Full maxilla and partial mandible reconstruction- case report and considerations regarding necessary number of implants and the necessity for the incorporation of a rigidly cemented metal-enforced first bridge for immediate loading treatment protocols

Authors
Ihde Stefan[1]
Ihde Antonina[2]

Abstract
Corticobasal implants (Strategic Implant®) are first choice devices when it comes to treating full jaws or segments with implant-based constructions [1]. Contrary to traditional implants, which are designed for "osseointegration", corticobasal implants are osseofixated in the 2nd or 3rd cortical bone. Since peri-implantitis does not occur in corticobasal implants, the treatment provider can easily increase their number to gain more contact areas with the cortical and thereby more primary stability.

In this case report we present the procedure and explain the choice of positions for the implants and for their number.

1 Implantologist, Stomatolog-Chirurg (RU), International Implant Foundation, Department of Evidence and Research, Munich, Germany.
2 Prosthetic Implantologist, International Implant Foundation, Head of Dental Implant Faculty (2019 -), Munich, Germany. **Corresponding author:** antonina.ihde@gmail.com

Corticobasal implants provide safe grounds for fixed prosthetics, if the rules of the Technology of the Strategic Implant® are obeyed.

Key Words
Immediate functional loading;
Strategic Implant®

Introduction
Traditional dental implants hardly allow to carry out treatment protocols in immediate functional loading, because in most patients the necessary amount of bone is missing and the rules are not widely known. Many dentists still believe that specific implant surfaces have influence on the healing time and they are still waiting for the "most advanced (endosseous) implant surface" to appear on the market, the surface which will finally allow for immediate loading [2-9]. Unfortunately, bone biology tells us that this will quite surely never happen [5-8].

3D-augmentations of the jaw bone with bone stubstitutes in combination with immediate loading do not make much sense either, because augmentation material first has to remodel and integrate with the existing bone [10]. Corticobasal implants bypass this problem by using (sometimes remote) cortical bone areals in "strategic positions" for anchorage and, as a result, they povide the possibility of immediate functional loading [11].

It is, however, necesary to follow a strict prosthetic protocol for these implants, because uncontrolled masticatory forces may cause overload osteolysis around the load transmitting surfaces. In the maxilla, the floor of the nose and the pterygoid

plate of the sphenoid bone as well as the disto-palatal region are prefered place for anchorage. Lazarov as well as Dobrinin et al. have shown, that these sites resulted in very high survival rates for the implant, regardless of the type of prosthetic construction built thereon [12, 13].

Material and Methods

A 46-year old, healthy non-smoking female patient requested dental implant treatment in the maxilla due to severe deterioration of the remnants of her dentition and limited chewing possibilities. Radiological examination revealed severely destroyed dentition in the maxilla and missing 1st and 2nd molars on the left side of the mandible, as shown in Fig. 1. The treament included removal of all the teeth in the maxilla and placement of three implants to in the place of tooth 36 also in an immediate loading procedure, Fig. 2.

After having received first metal-to-acryl bridge for the maxilla within three days, the patient remained with this bridge for 18 months. During this period massive abrasions on the maxilla bridge were observed which resulted in choosing MFC (metal-fused-ceramic) as material for the final bridge. The exchange of two implants was necessary, as the temporary bridge partly decemented leading to mechanical overloading of the bone around two implants.

Exchanging implants simultaneously with prosthetic construction is a standard procedure in corticobasal implantology. The new implant(s) must again reach healthy and mineralized (2nd) cortical anchorage in order to contribute to the load transmission [14]. However, it must be taken into consideration that implant constructions on eight or more corticobasal implants per jaw can be stable also with one or two implants fewer in function. In the mandible, it is not always recommended to place new implant into the place where the mobile implant was. In the maxilla, there are no such limitations [14].

Each corticobasal implant was placed following one or several of the defined methods for corticobasal implants [15]:

Implant Position	Method used
37	5a
17, 27	10
16	6, 8
15	6
13, 11, 21, 23	7a
24, 25	8

Table 1: *Overview of the methods used for the placement of all implants in the maxilla and for implant 37. Two compression screws in area 36 were just compressing the spongious bone without having basal cortical anchorage.*

The frontal group of the final bridge (Fig. 4) was positioned slightly anteriorly to the alveolar crest. After the extraction of the patients' own teeth the alveolar crest had undergone shrinkage, i.e. vertical and horizontal atrophy [16-18]. The tooth position in the bridge had remained unchanged however. This allowed for a good support of the upper lip and natural perioral function and speaking function compared to the pre-treatment conditions. When the technology of Strategic Implant® is applied, the points of anchorage are chosen independently of the (later) tooth position. Therefore, this concept (just as "All- on- 4" concept) [19-22] does not follow the older (in our view outdated and rather dangerous) methods in dental implantology, according to which the implant has to be positioned in the "prosthetically desired position" [23-28].

Both prosthetic constructions are stable, the patient eats without pain and very comfortably and she has been equipped with fixed bridges on implants over the last 5.5 years almost without interruption. The bridge exchange after 18 months took 2 days.

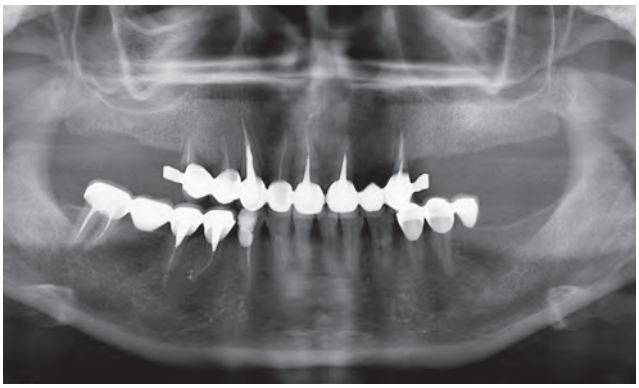

Fig. 1: *Chewing possibilites presented by the patient were rather limited, after the bridges in the maxilla became mobile and the retention for the removable posterior denture had been lost. The patient complained about condition of the maxilla.*

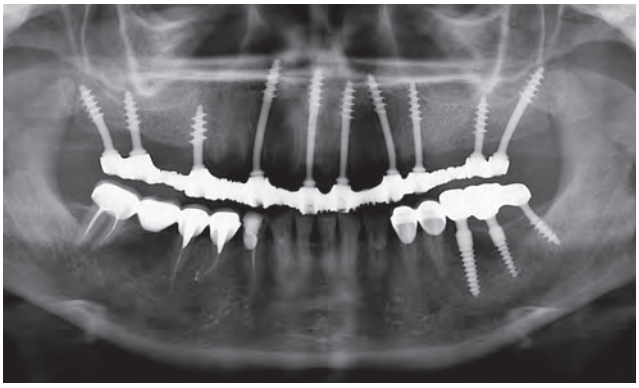

Fig. 2: *In the maxilla 10 BCS® implants were placed and splinted within 3 days with the help of a fixed metal-to acrylic bridge. Instead of the pontic for tooth 36, a full crown on three implants (anteriorly 2 compression KOS® screws, and one cortico-basal implant) was installed. Contacts for the mandible were restricted to teeth 4-6 on both sides. No front contacs were installed, neither in occlusion nor in mastication. This very successful concept for immediate loading was described by Ihde & Ihde [29].*

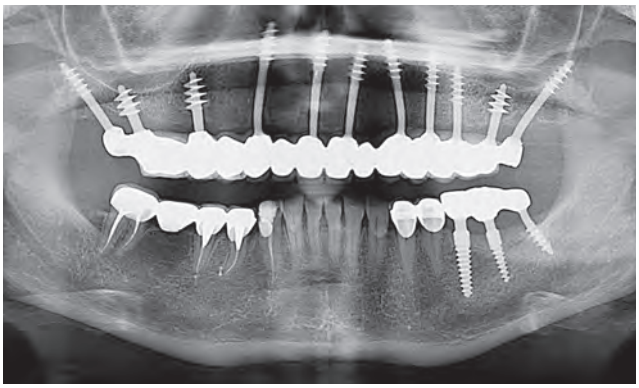

Fig. 3: *During prosthetic bridge exchange procedures in the maxilla to a final metal-ceramic bridge, the implants in area 15, 17 and 27 seemed mobile. They were removed and immediately replaced by two implants with larger diameters (4.6 mmd in area 15, and 5.5mmd in area 17) and in area 27 one implant was added. Then, the bridge was fabricated and cemented within three days. The bone level has stayed unaltered from the beginning, no peri-implant infection or bone loss have appeared.*

Fig. 4: *A highly aesthetic MFC bridge in the maxilla with the upper frontal group being positioned anteriorly to the crest, leaving sufficient gaps betwen the bridge and the mucosa for easy cleaning and self cleaning.*

Results

18 months after the onset of the treatment the first long term temporary bridge was replaced with MFC bridge in the maxilla (lower segment construction has been produced in MFC from the beginning). Both prosthetic constructions have been stable, the patient eats without pain and very comfortably and has been equipped with fixed bridges on the implants over last 5.5 years almost without interruption. The bridge exchange after 18 months took 2 days. Control OPG was taken after 5.5 years revealing no irregularties, as shown in Fig. 3.

As for the final bridge material zirkonium and metal-to-composite were also available. Composite shows less abrasion compared to unfilled acryl and it allows for bite raising. Nevertheless, this material was not chosen, beause strong abrasion was observed on the 1st long term temporary bridge. Zirkonium, on the other hand, is very hard and the adjustments of the masticatory slopes (during check-up visits) are hard to perform on this material. Therefore we opted for metal-fused-ceramic bridge.

Discussion

(Private) health insurers tend to request that a small number of implants are being placed in order to reduce the teatment costs which they have to cover. Likewise,

the necessity for an immediate fixed splinting and second bridge are questioned by such companies.

Corticobasal implants utilize only the 2nd or 3rd cortical bone for anchorage, their shaft (initially) only passes through the spongious bone between the 1st and 2nd cortical without creating any traction. Hence, the spongious bone around the vertical polished shaft does not contribute to the load transmission of the implants, unless after some months. Moreover, this (typically endosseous) implant part osseointegrates. It is advisable to place rather more than "enough" implants in the first place because we cannot know if all the implants are going to be stable after the first few months of healing under full functional load. Increasing the number of implants (compared to the number used in 2-stage implantology) also reduces the chances of damages that may be done due to errors in occlusion and wrong (e.g. unilateral) mastication.

2-stage implantologists are typically not aware of the importance of bilateral and equal function and loading, because by the time they load the implants, the implants are already well osseointegrated. Wrong loading will usually not destroy the osseointegration, however other damages will occur: fractures of prosthetic screws and abutments or even fractures of the implant or the whole prosthetic restoration [30-33].

This strategy is similar to the concepts known in traditional dental implantology, where plenty of implants are placed in the first stage of treatment, and those which have not osseointegrated will be removed before prosthetic procedures are even started. Hence traditional implantologists hope that enough implants will be available after the healing time is over. In corticobasal implantology, all implants are loaded immediately (i.e. within 72 hours). Right after they have been placed, the next big investment into prosthetics must follow. Placing a larger number of implants (i.e. 10-14 in the maxilla) reduces the risk of repeating the prosthetic phase if single implants lose cortical contact or if the cortical bone gets osteolytic through overload. Moreover, traditional dental implantology (2-stage implantology; 2-phase implantology) faces the unsolvable problem called "peri-implantitis".

We know today that the incidence of peri-implantitis in the maxilla increases significantly as soon as five or more such implants are placed there [34]. Hence implantologists who do not know the working principle of the technology wrongly criticise Strategic Implant® concept. Placing

so many 2-stage implants (10 or more in the maxilla) with large diameter and rough endossous surface would obviously end up in significant bone loss. Around Strategic Implant® implants peri-implantitis has never been reported, as well as bone loss beyond the natural atrophy (i.e. after extraction) [9].

In conclusion, advantages offered by Strategic Implant® system make it an obvious choice for clinicians. Replacing tooth 36 safely can require three implants as shown in this article. Those implants will be in full funtional loading from the beginning, because the masticatory system will not function propperly, if this important tooth is missing. This can create missloading in other areas of the skeleton and lead to unpredictable conditions and the stability of dental implants may suffer from the change in function.

Conclusion

The Strategic Implant® technology offers simple solutions for fully or partially edentulous jaws. Placing enough cortically anchored implants (i.e. ten or more in the maxilla and eight in the mandible) is essential to achieve sufficient stability especially during the first 3-6 months when the postoperative osteonal remodelling takes place.

Single molars are replaced by two or three implants due to the expected high chewing forces in that area.

We have to understand today, that for the permanten fixation of dental implants nothing works as reliably as (even the smallest amount) of cortical bone in its natural position (non transplanted).

References

1. Ihde S. Indications and treatment modalities with corticobasal jaw implants. Ann Maxillofac Surg 2019;9:379-86.
2. Albrektsson T., Branemark P., Hansson H., Lindstrom J. Osseointegrated titanium implants. Requirements for ensuring a long-lasting, direct bone-to-implant anchorage in man. Acta Orthop. Scand. 1981: 52, 155–170.
3. Davies J. Mechanisms of endosseous integration. Int. J. Prosthodont. 1998;11, 391–401.
4. Choi J., Sim J., Yeo I. Characteristics of contact and distance osteogenesis around modified implant surfaces in rabbit tibiae. J. Periodontal Implant Sci. 2017; 47, 182–192
5. Albrektsson T., Jemt T., Molne J., Tengvall P., Wennerberg A. On inflammation-immunological balance theory-A critical apprehension of disease concepts around implants: Mucositis and marginal bone loss may represent normal conditions and not necessarily a state of disease. Clin. Implant Dent. Relat. Res. 2019; 21, 183–189.
6. Brunski J. On Implant Prosthodontics: One Narrative, Twelve Voices - 2. Int. J. Prosthodont. 2018; 31, s15–s22.
7. Kwon T., Choi J., Park J., Yeo I. A Clue to the Existence of Bonding between Bone and Implant Surface: An In Vivo Study. Mater. 2019; 12, 1187.
8. Yeo I. Modifications of dental implant surfaces at the micro-and nano-level for enhanced osseointegration. Mater. 2020; 13(1), 89
9. Palka L, Lazarov A. Immediately loaded bicortical implants inserted in fresh extraction and healed sites in patients with and without a history of periodontal disease. Ann. Maxillofac. Surg. 2019;9:371-8
10. Gallucci G., Hamilton A., Zhou W., Buser D., Chen S. Implant placement and loading protocols in partially edentulous patients: A systematic review. Clinical oral implants research. 2018; 29, 106-134.
11. Ihde S, Palka L. Anchorage possibilities in case of a unilateral maxillary defect using the concept of Strategic Implant®. Natl J Maxillofac Surg. 2018;9(2):235–239. doi:10.4103/njms.NJMS_36_18
12. Lazarov A. Immediate Functional Loading: Results for the Concept of the Strategic Implant®. Annals of maxillofacial surgery. 2019; 9(1):78–88. doi:10.4103/ams.ams_250_18
13. Dobronin O, Lazarov A, Konstatntinovic V, Sipic O, Siljanovski D, Milicic B. Immediate-functional loading concept with one-piece implants in the mandible and maxilla – A multi-center retrospective clinical study. J Evol Med Dent Sci 2019;8:306-15.
14. Ihde S, Ihde A, Lysenko V, Konstantinovic V, Palka L. New systematic terminology of cortical bone areas for osseo-fixated implants in strategic oral implantology. J Anat 2016;1:7.
15. http://implantfoundation.org/en/consensus-16-approved-methods-2018-menu-en, (last visited 05 Jan 2020)
16. Johnson K. A study of the dimensional changes occurring in the maxilla following tooth extraction. Aust Dent J 1969: 14: 241–244.
17. Paolantonio M, Dolci M, Scarano A, d'Archivio D, di Placido G, Tumini V, Piattelli A. Immediate implantation in fresh extraction sockets. A controlled clinical and histological study in man. J Periodontol 2001: 72: 1560–1571.
18. Pietrokovski J, Massler M. Alveolar ridge resorption following tooth extraction. J Prosthet Dent 1967: 17: 21–27.
19. Malo P, Rangert B, Dvarsater L. Immediate function of Branemark implants in the esthetic zone: a retrospective clinical study with 6 months to 4 years of follow-up. Clin Implant Dent Relat Res. 2000;2:138–46.
20. Malo P, Rangert B, Nobre M. "All-on-Four" immediate-function concept with Branemark System implants for completely edentulous mandibles: a retrospective clinical study. Clin Implant Dent Relat

Res. 2003;5:2–9.
21. Malo P, Friberg B, Polizzi G, Gualini F, Vighagen T, Rangert B. Immediate and early function of Branemark System implants placed in the esthetic zone: a 1-year prospective clinical multicenter study. Clin Implant Dent Relat Res. 2003;5:37–46.
22. Malo P, de Araujo Nobre M, Lopes A, Moss SM, Molina GJ. A longitudinal study of the survival of All-on-4 implants in the mandible with up to 10 years of follow-up. J Am Dent Assoc. 2011;142:310–20.
23. Testori T, Bianchi F, Del Fabbro M, Capelli M, Zuffetti F,Berlucchi I, Taschieri S, Francetti L, Weinstein RL. Implantaesthetic score for evaluating the outcome: Immediateloading in the aesthetic zone. Pract Proced Aesthet Dent 2005:17: 123–130.
24. Moraschini V, Velloso G, Luz D, Barboza EP. Implant sur-vival rates, marginal bone level changes, and complicationsin full-mouth rehabilitation withflapless computer-guidedsurgery: a systematic review and meta-analysis.Int J Oral Maxillofac Surg 2015:44: 892–901.
25. Krennmair G, Seemann R, Weinlander M, Wegscheider W, Piehslinger E. Implant-prosthodontic rehabilitation of ante-rior partial edentulism: a clinical review. Int J Oral Maxillofac Implants 2011:26: 1043–1050.
26. Kan JY, Roe P, Rungcharassaeng K, Patel RD, Waki T, Lozada JL, Zimmerman G. Classification of sagittal rootposition in relation to the anterior maxillary osseous hous-ing for immediate implant placement: a cone beam computed tomography study. Int J Oral Maxillofac Implants 2011:26: 873–876.
27. Buser D, Martin W, Belser UC. Optimizing esthetics forimplant restorations in the anterior maxilla: anatomic andsurgical considerations. Int J Oral Maxillofac Implants 2004:19:43–61.
28. Grunder U, Gracis S, Capelli M. Influence of the 3-D bone-to-implant relationship on esthetics. Int J Periodon Restor Dent 2005:25: 113–119.
29. Ihde S, Ihde A. Cookbook Mastication IF Publishing, München, 3rd edition 2019: ISBN 987-3-945889-12-1
30. Korsch M, Walther W. Retrospective analysis of loosening of cement-retained vs screw-retained fixed implant-supported reconstructions. Quintessence Int. 2015;46 (7):583–589. doi:10.3290/j.qi.a34077
31. Nissan J, Narobai D, Gross O, Ghelfan O, Chaushu G. Long-term outcome of cemented versus screw-retained implant-supported partial restorations. Int J Oral Maxillofac Implants. 2011;26(5):1102–1107.
32. Lemos CA, de Souza Batista VE, Almeida DA, Santiago Júnior JF, Verri FR, Pellizzer EP. Evaluation of cement-retained versus screw-retained implant-supported restorations for marginal bone loss: A systematic review and meta-analysis. J Prosthet Dent. 2016;115(4):419–427. doi:10.1016/j.prosdent.2015.08.026
33. Gallucci GO, Avrampou M, Taylor JC, Elpers J, Thalji G, Cooper LF. Maxillary Implant-Supported Fixed Prosthesis: A Survey of Reviews and Key Variables for Treatment Planning. Int J Oral Maxillofac Implants. 2016;31 Suppl:s192–s197. doi:10.11607/jomi.16suppl.g5.3
34. Passoni BB, Dalago HR, Schuldt Filho G, et al. Does the number of implants have any relation with peri-implant disease?. J Appl Oral Sci. 2014;22(5):403–408. doi:10.1590/1678-775720140055

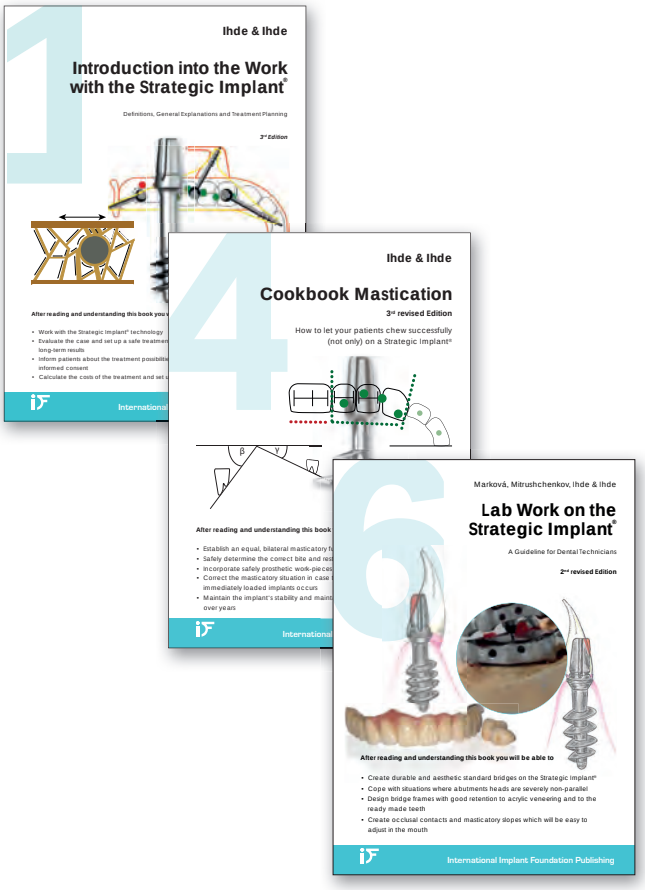

Educational Book Series

1 Introduction into the Work with Strategic Implant®
Edition 3, Order # 4448
Avaiable in

German	ISBN 987-3-945889-22-0
English	ISBN 978-3-945889-07-7
Hungarian	ISBN 978-3-945889-24-4
Polish	ISBN 978-3-945889-07-7
Romanian	ISBN 978-3-945889-24-2
Russian	ISBN 978-3-945889-08-4
Serbian	ISBN 978-3-945889-09-1

4 Cookbook Mastication
Edition 3, Order # 4447
Avaiable in

Bulgarian	ISBN 978-3-945889-03-9
German	ISBN 978-3-945889-26-8
English	ISBN 987-3-9851468-8-0
Hungarian	ISBN 978-3-945889-21-6
Polish	ISBN 978-3-945889-11-4
Romanian	ISBN 978-3-945889-23-7
Russian	ISBN 987-3-9851468-8-0 (2nd edition)
Serbian	ISBN 978-3-945889-06-0
Spanish	ISBN 987-3-9851468-8-0 (2nd edition)

6 Lab Work on the Strategic Implant®
Edition 2, Order # 4460

German	ISBN 978-3-945889-17-6
English	ISBN 978-3-945889-10-7
Hungarian	ISBN 978-3-945889-10-7
Romanian	ISBN 978-3-945889-27-5
Russian	ISBN 978-3-945889-14-5
Serbian	ISBN 978-3-945889-10-7
Spanish	ISBN 978-3-945889-13-8

Please send your order via e-mail to
publishing@implantfoundation.org
www.implantfoundation.org

or via regular postage mail to
International Implant Foundation
Leopoldstr. 116, DE-80802 München

Guide for Authors

ID publishes articles, which contain information, that will improve the quality of life, the treatment outcome, and the affordability of treatments.

The following types of papers are published in the journal:
Full length articles (maximum length abstract 250 words, total 2000 words, references 25, no limit on tables and figures). Short communications including all case reports (maximum length abstract 150 words, total 600 words, references 10, figures or tables 3) Technical notes (no abstract, no introduction or discussion, 500 words, references 5, figures or tables 3). Interesting cases/lessons learned (2 figures or tables, legend 100 words, maximum 2 references).

Literature Research and Review articles are usually commissioned. Critical appraisals on existing literature are welcome. Direct submissions to **publishing@implantfoundation.org**

The text body (headline, abstract, keywords, article, conclusion), tables and figures should be submitted as separate documents. Each submission has to be accompanied by a cover letter. The cover letter must mention the names, addresses, e-mails of all authors and explain, why and how the content of the article will contribute to the improvement of the quality of life of patients.