



Cranio-maxillofacial

# Implant Directions®

Vol. 6 N° 3 September 2011

English Edition



## FULL LENGTH ARTICLE»

RESTORING THE SEVERELY ATROPHIED POSTERIOR  
MANDIBLE WITH BASAL IMPLANTS: FOUR SURGICAL  
APPROACHES BROADEN THE INDICATIONS FOR FIXED IMPLANT  
RESTORATIONS IN THE MANDIBLE

IHDE S.  
VITOMIR S.  
IHDE A.

# OFFPRINT

## Editorial board

### Editor-in-chief

Prof. Dr. Stefan Ihde  
ihde@ihde.com

### Managing editor

Dr. Alexei Stugarev  
alexei\_stugarev@mail.ru

### Coordinating editor

N. N.

### Editorial board (in alphabetic order)

Henri Diederich med.dent, Luxemburg  
Dr. Yassen Dimitrov, Bulgaria  
Za. Stephan Haas, Germany  
Prof. Dr. Vitomir S. Konstantinovic, Serbia  
Carlos Mendez, Spain  
Dr. Richard Musicer, USA  
Dr. Gerald Schillig, Germany  
Dr. Katrin Tost, Greece

### Evidence reports and Critical Appraisals

IF Research & Evidence Dept.

### Single Issue Price

Euro 30

### Annual Subscription

Euro 120

### Copyright

Copyright ©2008 by  
International Implant Foundation  
DE- 80802 Munich / Germany  
www.implantfoundation.org

### Contact

publishing@implantfoundation.org

### CMF.Impl.dir.

ISSN 1864-1199  
e-ISSN 1864-1237

## Disclaimer

### Hazards

Great care has been taken to maintain the accuracy of the information contained in this publication. However, the publisher and/or the distributor and/or the editors and/or the authors cannot be held responsible for errors or any consequences arising from the use of the information contained in this publication. The statements or opinions contained in editorials and articles in this publication are solely those of the authors thereof and not of the publisher, and/or the distributor, and/or the IIF.

The products, procedures and therapies described in this work are hazardous and are therefore only to be applied by certified and trained medical professionals in environment specially designed for such procedures. No suggested test or procedure should be carried out unless, in the user's professional judgment, its risk is justified. Whoever applies products, procedures and therapies shown or described in this publication will do this at their own risk. Because of rapid advances in the medical science, IIF recommends that independent verification of diagnosis, therapies, drugs, dosages and operation methods should be made before any action is taken.

Although all advertising material which may be inserted into the work is expected to conform to ethical (medical) standards, inclusion in this publication does not constitute a guarantee or endorsement by the publisher regarding quality or value of such product or of the claims made of it by its manufacturer.

### Legal restrictions

This work was produced by IF Publishing, Munich, Germany. All rights reserved by IF Publishing. This publication including all parts thereof, is legally protected by copyright. Any use, exploitation or commercialization outside the narrow limits set forth by copyright legislation and the restrictions on use laid out below, without the publisher's consent, is illegal and liable to prosecution. This applies in particular to photostat reproduction, copying, scanning or duplication of any kind, translation, preparation of microfilms, electronic data processing, and storage such as making this publication available on Intranet or Internet.

Some of the products, names, instruments, treatments, logos, designs, etc. referred to in this publication are also protected by patents and trademarks or by other intellectual property protection laws (eg. «IIF», «IIF» and the IIF-Logo) are registered trademarks even though specific reference to this fact is not always made in the text.

Therefore, the appearance of a name, instrument, etc. without designation as proprietary is not to be construed as a representation by publisher that it is in the public domain.

Institutions' subscriptions allow to reproduce tables of content or prepare lists of Articles including abstracts for internal circulation within the institutions concerned. Permission of the publisher is required for all other derivative works, including compilations and translations. Permission of the publisher is required to store or use electronically any material contained in this journal, including any article or part of an article. For inquiries contact the publisher at the address indicated.

# Restoring the severely atrophied posterior mandible with basal implants: four surgical approaches broaden the indications for fixed implant restorations in the mandible

## Authors:

Stefan K.A. Ihde\* (DMD),  
Vitomir S. Konstantinovic (DDS,MD,PhD)  
†, Ihde A. (DMD)\*

\*From the Gommiswald Dental Clinic, Gommiswald/Switzerland and The Clinic of Maxillofacial Surgery, School of Dentistry, University of Belgrade, Serbia

## Abstract

Using basal implants in many indications has become a standard procedure. Basal implants enable the surgeon to place implants in atrophied mandibles with osseointegrated abutments and to equip them in an immediate load protocol. This way augmentations, bone transplants, distractions and similar additional operations are avoided.

The posterior mandible often presents itself extremely atrophied. Implantologists trained in the usage of basal implants can choose between four different treatment

procedures to equip this bone area with implants. The procedures are explained and compared to traditional treatment alternatives.

:Basal implants, TOI®, atrophied distal mandible, dental implants, immediate loading

## 1. Introduction

Achieving stability and «osseo-integration» for dental implants is considered today a safe and effective procedure. Also different techniques for creating more bone volume are today yielding acceptable results in the hands of the experienced treatment provider. Nevertheless the placement of root formed implants in the atrophied posterior mandible can be difficult and often even impossible. Adjunctive procedures for enlarging the bone volume increase the risks of the overall treatment and they reduce thereby the predictability. Cases of severe atrophy in the posterior mandible as shown in this publication still cannot be solved by using root formed implants with a reasonable chance for success.

Today's dental implant treatment faces other challenges, which are related to changes in social behaviour of the patients and their increasing access to information and mobility: more and more patients are willing to seek treatment anywhere in the world, they actively and independently search for modern treatment possibilities as they cannot know about the «main-

stream» in our profession. They compare prices and they search without borders. Treatment plans which include several steps of surgery are less attractive or simply rejected, because the costs of lost work-time and travelling add up to the total costs of treatment. In addition the willingness to wait for «the healing» of the bone and to suffer a multi-step treatment plan, and especially to accept collateral damages in bone donor regions is rapidly vanishing. This all advocates for the use of basal implants<sup>10</sup> as one option to avoid bone grafting.

The treatment options provided through the use of basal implants are available and have been improved for several decades<sup>3,10</sup> Prospective<sup>11,12</sup> and retrospective<sup>4,5,8</sup> studies have been published. The extremely atrophied mandible requires special surgical techniques and these techniques are described here. The success rate for basal implants is known to be around 97% within 3 – 5 years. In this article we do not provide data regarding the mentioned techniques for basal dental implants, because we do not distinguish between their use below and above the lower alveolar nerve. We have treated cases above and below the nerve during the past 10 years. Using the alternative strategies described in this article will not change the clinical outcome nor the success rate, it only allows to increase the number of treatable patients.

## 2. Case descriptions

For placing basal implants crestally to the nerve in the posterior mandible, approximately 2 – 3 mm of vertical bone above the lower alveolar nerve is necessary<sup>7</sup> and the morphology of the bone must allow the insertion of a bi-cortically anchored base plate and cover it as much as possible. The base-plate of these implants is 0.7 mm high and on top of the base-plate another 1-2 mm of native bone should be available. Some patients present with bone height not sufficient for placing root formed implants in the posterior mandible. They may be treated by using one of the following procedures:

### 2.1. Positioning the base plate below the bone canal of the mandibular nerve

Reports about the possibility of equipping the distal mandible while placing the base plates below the mandibular nerve were published<sup>7, 14, 16</sup>. One of the prerequisites for using this technique is the presence of a cortical around the bundle of inferior alveolar nerve and the accompanying vessel (Figs. 1 a-e are illustrating the procedure). If the presence of this cortical cannot be verified, the technique described in section 2.2. is recommended instead, because for osteotomies above the nerve, only a stable cortical boundary can securely keep the nerve in place and protect the bundle of nerves and vessels. The availability of this inner cortical can be verified during the operation by probing or pre-operatively with the help of a tomography.

Technique: The procedure should be carried out without administering a mandibular block, i.e. while the lower alveolar nerve is responding. This way the presence of a minimal distance to the nerve can be guaranteed. The Rr. buccales and the mental nerve are anaesthetized instead to allow for a painless flap preparation. Carrying out this procedure under full anaesthesia or a deep sedation results in a full or partial loss of control over the approximation to the nerve.

The full thickness flap is prepared on the centre of the alveolar crest (if there is such a crest) or lingually of the crest. The bone in the area of the 2nd molar then receives a thin vestibule-lingual incision. A hard metal cutter at sufficient speed is a good instrument for this first step. This cut should reach the bundle of nerve and vessels. In some cases the alveolar artery is positioned above the nerve and this may result in a bleeding before the nerve is reached. After opening the cortical which surrounds the vessels and nerve, it should be verified with a probe, that the canal is bordered by a cortical. The exact position of the nerve is verified through probing and with the help of the response of the patient to this probing. If the cortical is present and if the nerve's position is enough away from the lingual to allow a vertical osteotomy which reaches the centre of the mandible, the chosen position of the implant is appropriate. If the nerve presents itself too much to the vestibular side, a more distal location must be chosen. Note that the

lower alveolar nerve crosses over from the vestibular anterior exit (the: «mental foramen») to the lingual distal exit on the medial aspect of the ascending ramus. The more distal the implant position is chosen, the more likely the nerve will be found on the lingual side.

The vertical osteotomy is done from the vestibular side: For this osteotomy the vertical cutter 1.6mmd or 1.9mmd are used. This cut almost reaches the cortical around the mandibular nerve: the safety distance may only be about 1 mm or even less. The cut should reach a minimum of 2mm caudal to the internal cortical around the nerve and vessel.

If a large amount of (vertical) bone is available below the alveolar nerve, the installation of a double-basal implant is considered as an alternative to an implant with only one base-plate. For double-disk-implants the vertical cut must reach approx. 5mm deeper (caudally) than the lower alveolar nerve. As a next step the lateral (i.e. horizontal) osteotomy is carried through. This cut has to be performed with care in order to avoid penetration of the disc through the lingual cortical. Such a penetration could lead to a damage of the submental gland, or, in the anterior region of the anastomosis of the sublingual artery. The implant should be placed in such a way, that it does not get into direct contact with the alveolar nerve inside the bone. After preparing an adequate horizontal implant bed, the implant is inserted by tapping it in. The surgical procedure is

finished by tight suturing. The steps of this procedure are shown in Fig. 1 a-e. Clinical cases are presented and explained in Figs. 2a-c and 6.

The difficulty of this procedure lies not in the placement of the implant, but in the preparation and the deflection of the flap: the full thickness flap must be deflected to the vestibular and caudal in order to allow lateral access to the mandible with a rotating cutter of 9mm or 10mm. Mobilizing this flap is hindered by the bundle of the mental nerve and the vessel. On the other side of the flap both the facial artery and its vein must be protected at the same time.

Typical types of implants for this procedure are basal implants with a base plate diameter of 9 mm or 10 mm or implants with two disk rings of 7 mm – 10 mm diameter each. It is necessary to choose implants with a sufficiently long vertical part, as vertical bone growth along the implant must be expected as a result of the increased masticatory function<sup>6</sup>. Furthermore longer vertical parts allow an easier access for cleaning for the patient. The aesthetic demand of the patient regarding the distal mandible is minimal.

## **2.2 Placement of the basal implant after caudalisation of the mandibular nerve**

In cases where the alveolar nerve and the artery are not embedded in a bone canal, an infra-nerval placement may carry the danger of damaging the nerve. Usually, in

this situation, the distal mandible does not hold any bone inside the corticals, because it has developed towards a hollow bone. The bone contains a mucocelae-like bag of soft tissue and this bag is only slightly attached to the inner cortical. With the help of a periodontal probe or sinus-lift instruments the bag can easily be detached from the surrounding cortical. The membrane is not prone to a rupture and if a rupture occurs there are no problems associated to this. As soon as the membrane is detached on a wider area, the «bag» will sink down and shrink. The lower alveolar nerve and the artery will sink down inside the bag and with it. Now the supra-nerval osteotomy and subsequent implant placement are possible. It is not necessary that basal implants are in contact with bone or anything else at their central portion. The stability is gained solely by bi-cortical engagement. The slots created for the osteotomy will heal quickly and in some cases new woven bone generation inside the mandible may occur. The surgical steps for this procedure are illustrated by Figures 3 a-f, as it is difficult to show the procedure (which takes place inside the mandible) by photographs.

## **2.3 Implant placement in the anterior part of the mandibular ramus**

In cases when the implants can be placed neither below or above the mandibular nerve, the surgeon may evaluate a more distal region as an alternative position for the implant. Placing the implant higher, as

shown in Fig. 4, is a good option and not connected with problems if the vertical dimension should be restored<sup>9</sup>.

In the ascending ramus area the mandibular nerve gains more distance to the anterior border of the crest and this allows the placement of the implant there. If the depth of the slot is reduced, parts of the base plate may be left peaking out to the anterior. The implant may receive an additional fixation through a cortical bone screw.

#### **2.4 Application of basal implants as sub-periosteal implants.**

In cases of severe atrophy, especially if the patient suffers from osteoporosis, basal implants may be placed in the manner of sub-periosteal implants. Implants with a length of 33 and 43mm are available. The diameter of the central base-plate is 9mm.

The implant is fixed in the area of the 2nd premolar and in the ascending mandibular ramus with bone screws. Over the struts PRF-membranes may be placed to enhance new bone formation. Care must be taken, to avoid damage to the alveolar nerve through the bone screw: the maximum length of 6mm should not be exceeded and the screw should be directed away from the area of the nerve's transition. A clinical example for this procedure is shown in Fig. 5

### **3. Discussion**

As long as 3 – 4mm vertical bone is available above the mandibular nerve canal, the placement of basal implants could be

possible. However, careful placement and advanced experience in basal implants are required as there is anecdotal evidence that some of the attached complications to use basal implants can be: fracture of the implant, iatrogenic mandibular fracture and altered nerve sensation. In the past 15 years the authors have placed approximately 5.000 basal implants in various indications. Complications have been seen mainly in the first years, at a time when the surgical procedure had not been fully established and the designs of the basal implants were not as advanced as they are today. We have not seen the mentioned complications in implants placed after approx. 2002. Admittedly the technique requires a considerable amount of surgical skill, a good overview, and strict prosthetic concepts. The ability to use this device virtuously, requires experience. We observe today, that an increasing number of dentists in all age groups accept the burden of learning all these skills, because they understand, that the concept really works well and it avoids the hazards of bone augmentations, waiting («healing») time and costly intermediate prosthetic solutions.

#### **3.1. Infra-nerval placement and nerve caudalisation**

Placing the base plates below the mandibular nerve seems an astonishing solution. It is in fact a simple and functional solution, and it requires a 3-dimensional imagination of the bone site. The technique



utilizes the available bone and avoids bone buildups. A theoretical disadvantage may be that the mandible is too much weakened by the osteotomy especially in patients suffering from a pronounced osteoporosis. In these cases the sub-periosteal placement of basal implants (as described in section 2.4 of this article) may be the preferred method of treatment, especially if the total bone volume is really low.

One of the prosthetical problems associated to a pronounced atrophy can be the lateral position of the vertical implant part: as the atrophy of the mandible is associated with a centrifugal resorption (i.e. a widening of the distance between the left and the right distal horizontal ramus of the mandible). To cope with this technical abutments outside of the tooth arch of the bridges should be installed. Alternatively the bridge may be designed in a cross-bite situation. In our view both solutions are not connected with any disadvantages for the patients.

To access the mandible from the lateral aspect, the flap has to be dislodged considerably. A slight mobilization of the mental nerve is sometimes necessary to allow the necessary deflection of this flap. This part of the procedure may be associated with a transitional post-operative paraesthesia. Inserting the implants from the lingual side of the mandible is not an option in cases of severe atrophy, because this approach would require a removal of the mylohyoid muscle. When approaching from the vestibular side, the facial artery and its vein

must be protected meticulously with the help of a broad spatula or an instrument in the shape of a soup spoon. Bleedings out of these vessels are considerable and inconvenient. They are however quite easy to manage, as compression against the body of the mandible is possible and the access for suturing is good.

The question, whether or not infra-nerval placement of the implant is indicated, may be decided during the surgical intervention. A 3D-Tomography may be useful to decide this question and to prepare the necessary stock of implants, but it will not be helpful during the intervention itself. The trained surgeon will have no difficulty in exploring the width of the mandible intra-operatively to choose the correct implant.

### **3.2. Bone driven implant choice and placement**

One of the advantages of basal implant designs is the usage of resorption-stable bone areas which are not necessarily located below to the masticatory surfaces.<sup>7,10</sup> As the ascending ramus of the mandible is a stable bone with little tendency to resorb, it is only logical to search for bridge anchorage there. It is possible to either place the implant there, or to fix holding struts in this region.

If the implant is placed in this far distal position, the vertical position of the abutments will be quite high and the connection pieces to the bridge must be directed caudally. This may appear a bit unconventional or unusual on the



panoramic radiography. The surgeon as well as the prosthodontist has to take care that neither the abutments nor the connection struts interfere with the maxillary dentition. Restoring an adequate vertical dimension is important to gain the necessary space for lateral movements of the mandible.

As it may be difficult to create a common direction of insertion for all crowns of a full lower bridge, basal implant designs with internal screw connection may be used at least in the distal mandible. Screwable designs can be combined with one-piece basal implants designed for cementation and they require less vertical space.

### 3.3. Sub-periosteal placement of basal implant designs<sup>1</sup>

The purely sub-periosteal application of basal implants seems at first glance a step back in implantology, as the so called sub-periosteal implants (subs) are considered outdated or old fashioned. The number of practitioners who are able to place such custom made implants is however low and it is also difficult to find a laboratory which could fabricate subs. Using specially designed basal implants in the way described here, overcomes a number of problems earlier sub-periosteal designs and concepts were accompanied with:

- only one surgical intervention is necessary;
- no impression of the bone has to be taken;

- the extended implant frame does not have to be designed nor casted and it is fixed by conventional, cortically anchored bone screws;
- stress-free adaptation of the implant on the bone site is achieved by the surgeon;
- tensions between the implants can be avoided by precise work-pieces from the dental laboratory;
- if one implant fails, only this implant will be replaced, while the others may stay in place. This reduces the necessary effort in cases of complications. Earlier designs of one-piece subs for the whole jaw had to be removed as a whole in case a complication occurs.

The screw-on-technique with basal implants, i.e. the sub-periosteal use of those implants seems especially advantageous in the following cases:

- in cases of severe atrophy, when the mandible has a vertically reduced bone height of (incl the nerve) of 6mm or less;
- if less than 3mm of bone is available on top of the mandibular nerve;
- in cases of moderate or severe osteoporosis, if the danger of a post-operative fracture of the mandible has to be considered.

The bone screws have to be chosen and placed with care, because they may reach through the cortical into the void space inside the mandible and cause damage to the alveolar nerve.

### 3.4 Treatment alternatives

Traditional treatment alternatives in cases of advanced atrophy of the mandible are:

1. Bone block augmentation.
2. Vertical distraction or horizontal bone split.
3. Short implants.

Even if the invasiveness, the collateral damages, and the additional costs of (block-) augmentations onto the mandible are accepted by the patient, the additional risks of this procedure must be taken into account. Soft and hard tissue complications in bone block augmentations can affect up to 50% of the cases<sup>2</sup>, with the implant failure rate adding up. Complications are more frequent in the mandible than in the maxilla.

Short (root formed) implants are an alternative and yield acceptable results, as long as at least 5mm of vertical bone is available<sup>13,18</sup>. However this treatment option provides two disadvantages: traditional short implants cannot be used in immediate load procedures, and due to their two stage design the demand for attached gingiva in the mucosal penetration area and the demand for meticulous cleaning limits the use. In the cases of severe atrophy as shown in Figs. 6, 15, 16 their use is clearly not indicated, because this minimal amount of bone on top of the lower alveolar nerve was not present pre-operatively.

Vertical bone split procedures<sup>17</sup> yield acceptable results in the hands of the trained practitioner with experience. The

aim of this procedure is to widen the ridge without fracturing it, and to simultaneously insert traditional two stage implants. This procedure is useful, if enough vertical bone is given pre-operatively, to insert at least short types of conventional implants.

Horizontal bone split procedures (distractions, bone interpositions) may also be used in order to increase bone volume. Essential part of this procedure is a transosseous cut through the bone and to mobilize a cortical lid. We consider it a disadvantage that in cases of failure the mobile crestal segment of the bone gets lost. For us it is difficult to understand, why this top part of the bone is mobilized deliberately, if an incomplete bi-cortical horizontal osteotomy already allows the insertion of the basal implant and the immediate completion of the case (without any further necessity of increasing the bone volume, transporting bone, a second stage surgery, etc.). Searching the literature, we found a number of case reports on alveolar distraction, but we did not find a single prospective or retrospective cohort study on distractions in the atrophied distal mandible and subsequent implant placement. This indicates, that the method of vertical distraction as a pre-implantological treatment step seems not to be widely used nor explored in detail, although it is a useful method for other cranio-maxillo-facial purposes and in the field of the orthopaedic surgery.

In our view the traditional bullet-shaped screw designs are not an option for

treating cases as discussed here. As traditional two stage designs feature internal screw connection, they require not only bone height, but also bone width. Their surface is roughened and the mucosal penetration diameter is large. To prevent infections and bone loss, attached gingival should surround the implant. Even if this is given, the effort for successful (professional and individual) cleaning is large because the sites are difficult to reach in cases of pronounced atrophy.

As most patients simply request «fixed teeth» and not «more bone volume», the search for treatment options should be directed to the application of suitable implant designs rather than to bone buildup procedures.

#### 4. Conclusion

In our view, restoring the atrophied distal mandible with basal implants and splinting them through the bridge in an immediate load procedure is a safe and effective procedure<sup>8</sup>. The use of basal implants avoids the risks and hassles of bone build-ups and distractions. In case the posterior mandible is extremely atrophied, the surgeon has 4 options to treat:

- Infra-nerve implant placement.
- Placement of basal implants after caudalisation of the alveolar nerve and the vessel.
- Placement of basal implants in the anterior part of the ascending ramus of the mandible.

- Application of basal implants as subperiosteal implants.

By using any of the above techniques, all mandibles may be equipped with basal implants and fixed restorations. Immediate splinting (and thereby loading) as well as a symmetrical functional loading of the bridge are mandatory for the success of the procedure. At the same time this possibility meets exactly the expectations of the patients.

The methods discussed in this article are considered by the authors to be a superior alternative to the traditional techniques of increasing the bone volume, such as distraction-osteogenesis and vascularized or non vascularized bone block transplants.

**Competing interests:** None declared

**Funding:** None

**Ethical approval:** Not required

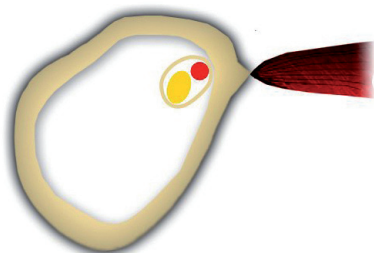


Fig. 1a: Schematic crosscut through the atrophied distal mandible: The lower alveolar artery and the nerve are located under the cortical roof of the bone and lingually, near the attachment of the mylohyoid muscle. A cortical around the vessel and the nerve is in this case given.

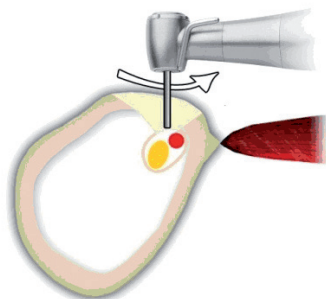


Fig. 1b: To find the artery and the nerve, a small vestibule-lingual slot is prepared, using a high speed carbide cutter with careful brushing movements. The position of the nerve can be verified safely, if no mandibular block was administered.

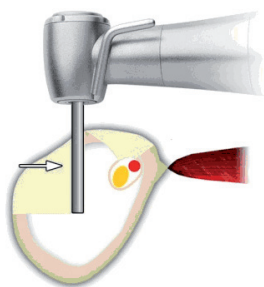


Fig. 1c: After localizing the caudal border of the mandibular canal. The depth for the vertical osteotomy is determined. This osteotomy is carried out with a vertical cutter of 1.6 or 1.9 mmd, and half the way through the bone.

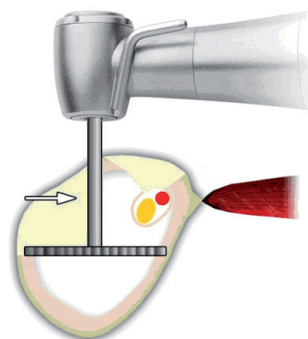


Fig. 1d: After the vertical osteotomy is ready, horizontal cutters are used to finish the osteotomy for the lateral implant. Note that in many cases the width of the bone in its lower aspect differs from the width near the attachment of the mylohyoid muscle. A 3d-tomography may help to choose an implant and to determine the necessary diameter of the cutter.

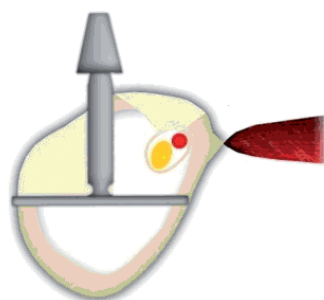


Fig. 1e: Bicortical engagement (lingual & vestibular) must be achieved in order to provide immediate stability for function and an uneventful osseointegration of the basal implant. Note that if the anchorage is not cortical, the spongy bone would yield during function, especially while the post-operative remodelling is under way.

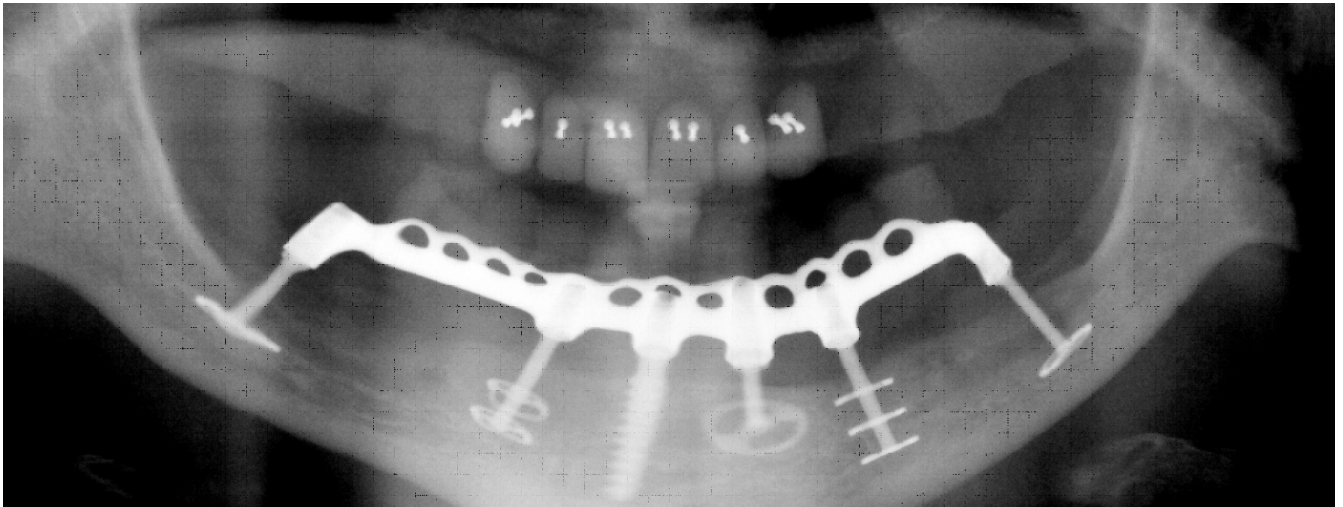


Fig. 2a: Panoramic overview on a mandible with six implants. Both distal implants (TOI, Biomed Est., Liechtenstein) were placed below the lower alveolar nerve.

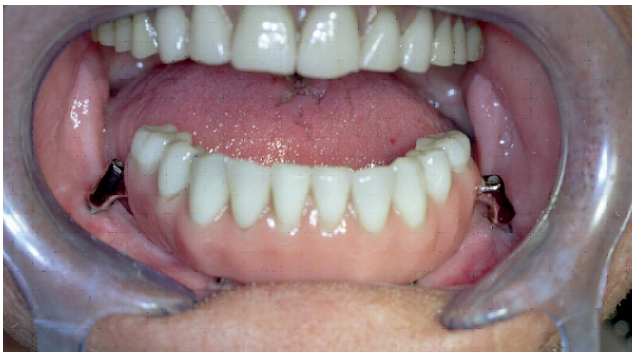

Fig. 2b: It is owed to the centrifugal pattern of atrophy in the mandible, that the distal implants are usually positioned vestibular to the tooth arch and technical abutments are necessary to connect the implants to the bridge. A casted metal frame with sufficient thickness is mandatory to ensure that masticatory loads are distributed between all implants. The tooth arch is designed and placed in ideal spatial relationship to the skeletal structures, whereas the implants utilize the resorption stable bone wherever it is available. In cases of severe atrophy this principles of reconstruction are a feasible alternative to "prosthetically driven implant placements" and "emerging profiles".

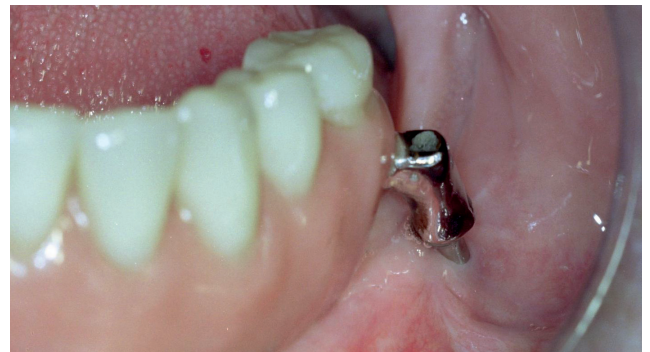

Fig. 2c: Detail of the same case, Region 37. Vertical bone growth on the lingual side of the vertical implant part is a typical reaction to the increased masticatory function after the installation of a fixed dentition. Note that due to the thin and polished nature of the vertical implant part, the implant may be placed even though only mobile mucosa is surrounding its penetration area.



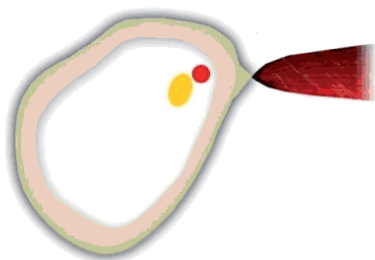


Fig. 3a: Schematic cross-cut through the atrophied distal mandible: The lower alveolar artery and the nerve are located under the crestal cortical roof. Their position is lingual, near the attachment of the mylohyoid muscle. A cortical around the vessel and the nerve is not given. The nerve and the vessel are embedded inside a mucoselae-like substance and this substance is enveloped inside a thin membrane which is attached to the endosteum of the mandible. In such a case, the cortical around mandibular canal is not visible on the panoramic picture nor on a CT.

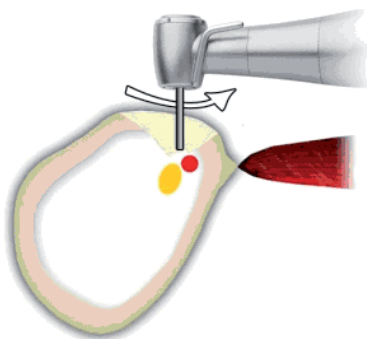


Fig. 3b: In order to localize the nerve and the artery a hard metal cutter is used, while applying careful brushing movements. The position of the nerve can only be verified, if no mandibular block was administered. If the mandibular artery is positioned on top of the nerve, bleeding may occur. The bleeding may be significant, if the anterior dentition of the mandible is still present. The fact that in this case no cortical is present around the nerve-vessel-bundle can be verified by probing.

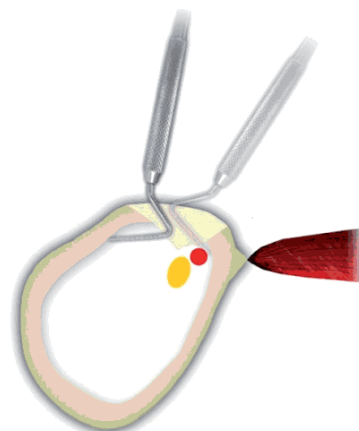


Fig. 3c: With the help of a periodontal probe or a small spatula the bag holding the jelly-like substance inside the hollow mandible is slowly detached from the endosteum. The "bag" is carefully disconnected from the surrounding bone. Keeping the instrument constantly in contact with the inner surface of the bone minimizes the risk to tear open this "bag".

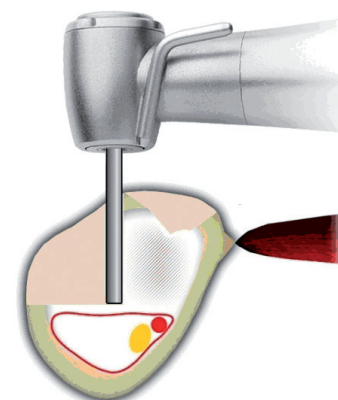


Fig. 3d: As soon as the bag collapses caudally, the artery and the nerve will sink down as well, because they are inside of this "bag". This way enough space is created for the vertical cut, which can be performed without damaging endangered structures, and leaving even the bag intact. After the vertical cut has been done, the inside of the mandible can be explored easily.

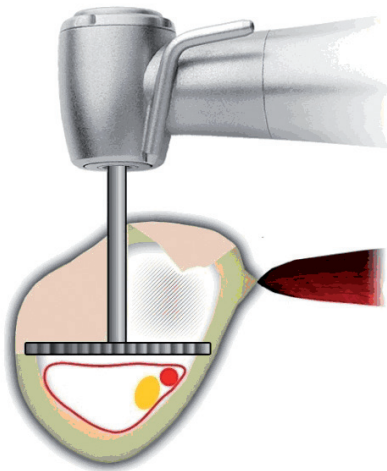


Fig. 3e: After the vertical osteotomy was performed, the lateral osteotomy can be performed safely.

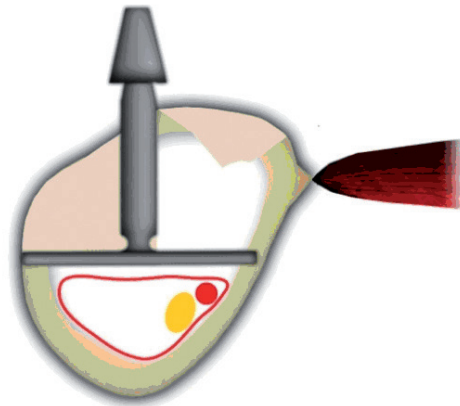


Fig. 3f: The basal implant may then be inserted in a bi-cortical manner into the empty space of the mandible, above the artery and the nerve.

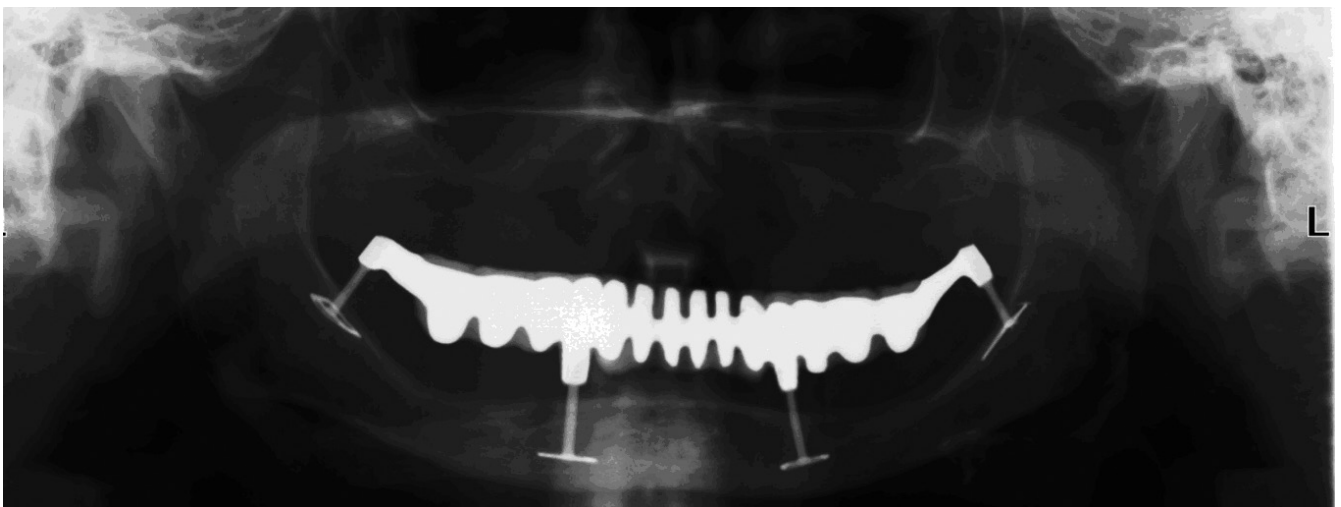


Fig. 4: Severely atrophied mandible, equipped with basal implants, nine years post-operatively. The base-plates of the anterior implants are positioned below the mental foramen. Both distal implants are placed in the vertical part of the mandibular ramus. Placing the base-plates of the anterior implants below the mental nerve is possible without any problems, because there is no need to localize or dislocate the nerve. The surgeon must make sure however, that there is no "loop" of the nerve.

Note that due to the thin and polished nature of the vertical implant parts, no peri-implant infections can possibly develop. The bone remained in its original shape and height.



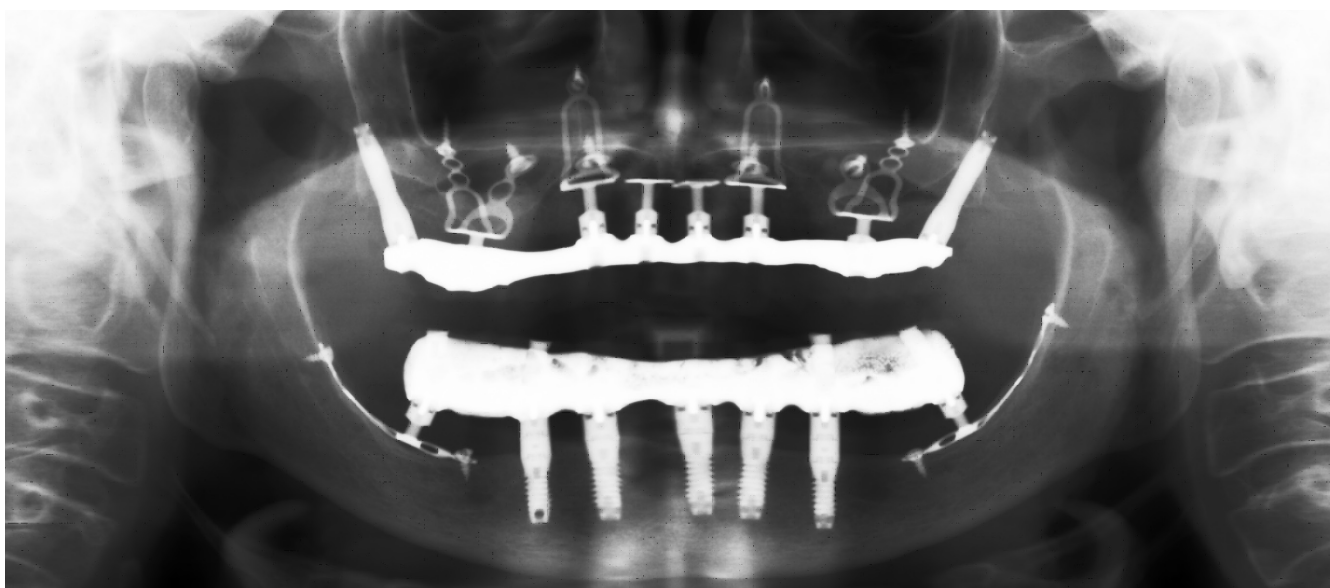


Fig. 5: In this case two adaptable basal implants (Diskimplant, Victory, Nice, 9 x 33 mm) were placed sub-periostally and connected to the anterior bullet-type implants in an immediate load protocol. The implants were secured with cortical bone screws (Figure from (1), with permission of the publisher).

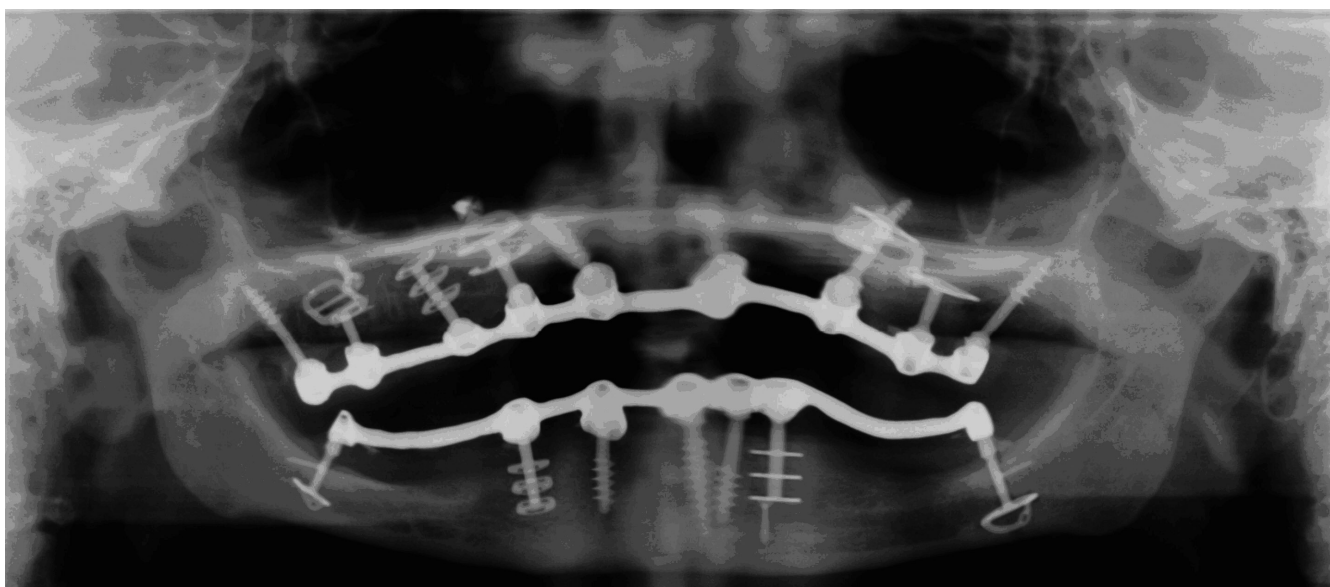


Fig. 6: Panoramic overview on a mandible with six implants. Both distal implants (TOI, Biomed Est., Liechtenstein) were placed below the lower alveolar nerve. The treatment in both jaws was done in an immediate loading protocol.

## References

1. Ansel A., Menetray D., Cotton P., Stenger A. Clinical Research: Maxillary atrophy and the techniques of diskimplants – basal implantology: clinical application. (Article in French) CMF Impl. Dir 5 (2) (2010) pp. 48 – 62.
2. Chaushu G., Mardinger O., Peleg M. Analysis of Complications Following Augmentation with Cancellous Block-Allografts. J. Periodontol. 2010 Aug.
3. Donsimoni J.M., Dohan D. Maxillo-facial support-plate implants: prosthetical concepts and technologies, rehabilitation of both jaws, maxillo-facial reconstructions, partial rehabilitations, corrective interventions, meta-analysis. 1st part: prosthetic concepts and technologies (Article in French) Implantodontie 13 (1) (2004), pp. 13-30.
4. Donsimoni J.-M., Gabrieleff M., Bernot P., Dohan D. Maxillo-facial support-plate implants: prosthetical concepts and technologies, rehabilitation of both jaws, maxillo-facial reconstructions, partial rehabilitations, corrective interventions, meta-analysis. 6th part: A meta-analysis? (Article in French) Implantodontie 13 (4) (2004), pp. 217-228.
5. Ihde S., Mutter E. Treating segments in the posterior jaws with basal implants when the bone supply is reduced. Retrospective study on 228 cases with 275 consecutively placed basal implants (Article in German), Deutsche Zahnärztl. Zeitschr. 58 (2) (2003), pp. 94 – 101.
6. Ihde S. Functional adaptation of the bone height after placing basal implants Implantodontie (Article in French) Implantodontie 12 (1) (2003), pp. 23-33.
7. Ihde S.(Edt.) Principles of BOI, Springer Verlag, Heidelberg, 2005.
8. Ihde S. Outcomes of immediately loaded full arch reconstructions on basal implants and teeth in the mandible: retrospective report on 115 consecutive cases during a period of up to 134 months CMF Impl Dir 3 (1) (2008), pp. 50-60.
9. Ihde S., Rusak A. Case Report: Treatment of a severely resorbed mandible with endosseous implants in an immediate loading protocol. CMF Impl. Dir. 4 (4) (2009), pp. 150 – 153.
10. Ihde S., Ihde A.(Edts.) Immediate Loading, International Implant Foundation Publishing, Munich/Germany, 2011.
11. Kopp S. Basal implants: a safe and effective treatment option in dental Implantology; CMF Impl. Dir. 2 (3) (2007), pp. 110-117.
12. Kopp S., Bienengräber V., Ihde S. Basal implants as a solid base for immediately loaded full arch bridges. Dental Forum 37 (1) (2009), pp. 51-60.
13. MacDonald K., Pharoah M., Todescan R., Deporter D. Use of sintered porous-surfaced dental implants to restore single teeth in the maxilla: a 7 – 9 years follow up. Int J Periodontics Restorative Dent. 29 (2) (2009), pp.191-199.

14. Malinovski I., Sidorov D., Rusak A. Conventional and basal implant therapy. A comparison and case report. *CMF Impl. Dir.* 4 (2) (2009), pp. 118 – 124.
15. Scortecchi G., Bourbon B. Prosthetics on Diskimplants. *RFPD Actualités* 31 (1) (1991), pp. 21-29.
16. Sohn DS, Lee HJ, Heo JU. Immediate and delayed lateral ridge expansion technique in the atrophic posterior mandibular ridge. *J. Oral Maxillofac Surg* 68 (9) (2010), pp. 2283-90.
17. Urdaneta RA, Rodriguez S., McNeil DC, Weed M., Chuang SK. The effect of increased crown-to-implant ratio on single-tooth locking taper implants. *Int J Oral Maxillofac Implants.* 25 (4) (2010), pp.729-743.





## EDUCATIONAL VIDEO SERIES

### Maxillary Implant Placement

1 CRESTAL & BASAL IMPLANTS  
Order Nr. 6667

2 AND REPLACING REPLACE®  
Order Nr. 6669

Each DVD contains approx. 20 minutes of oral surgery. With explanations in english and german language.

€ 35,00

Please send your order via e-mail to:  
[publishing@implantfoundation.org](mailto:publishing@implantfoundation.org)  
[www.implantfoundation.org](http://www.implantfoundation.org)

or via regular postage mail to:  
**International Implant Foundation**  
Leopoldstr. 116, DE-80802 München

## Guide for Authors

ID publishes articles, which contain information, that will improve the quality of life, the treatment outcome, and the affordability of treatments.

The following types of papers are published in the journal:

Full length articles (maximum length abstract 250 words, total 2000 words, references 25, no limit on tables and figures). Short communications including all case reports (maximum length abstract 150 words, total 600 words, references 10, figures or tables 3) Technical notes (no abstract, no introduction or discussion, 500 words, references 5, figures or tables 3). Interesting cases/lessons learned (2 figures or tables, legend 100 words, maximum 2 references).

Literature Research and Review articles are usually commissioned.

Critical appraisals on existing literature are welcome.

Direct submissions to:

[publishing@implantfoundation.org](mailto:publishing@implantfoundation.org).

The text body (headline, abstract, keywords, article, conclusion), tables and figures should be submitted as separate documents. Each submission has to be accompanied by a cover letter. The cover letter must mention the names, addresses, e-mails of all authors and explain, why and how the content of the article will contribute to the improvement of the quality of life of patients.